

The Secondary Glaucomas

Blair Lonsberry, MS, OD, MEd., FAAO

Professor of Optometry

Pacific University College of Optometry

blonsberry@pacificu.edu

Disclosures:

- Maculogix: advisory board
- Sun Pharmaceuticals: speakers bureau,
- Avellino: advisory board,
- Dompe: advisory board,
- RVL Pharmaceuticals: advisory board

Expected Learning Outcomes

- Needs Assessment:
 - To enable optometrists to provide care for patients with secondary forms of glaucoma.
- At the end of the presentation, attendees should be able to:
 - understand what constitutes a secondary glaucoma
 - recognize a patient suffering from neovascular glaucoma and the appropriate treatment and management strategies.
 - recognize a patient suffering from pigment dispersion syndrome and the potential development of glaucoma and review the appropriate treatment and management strategies
 - recognize a patient suffering from pseudoexfoliation syndrome and the potential development of glaucoma and review the appropriate treatment and management strategies
 - recognize a patient suffering from lens induced glaucomas including phacomorphic and phacolytic, their diagnosis, treatment and management

The Secondary Glaucomas

- most basic approach is to separate the various types of glaucoma into two categories:
 - secondary open-angle and
 - secondary narrow or closed-angle glaucoma
- classification may be based on:
 - the etiology of the disease or
 - the mechanism by which the elevation in IOP is produced

The Secondary Glaucomas

- secondary glaucoma may be:
 - congenital,
 - occur as a result of another ophthalmic disorder,
 - or be induced by or follow trauma or intraocular surgery.

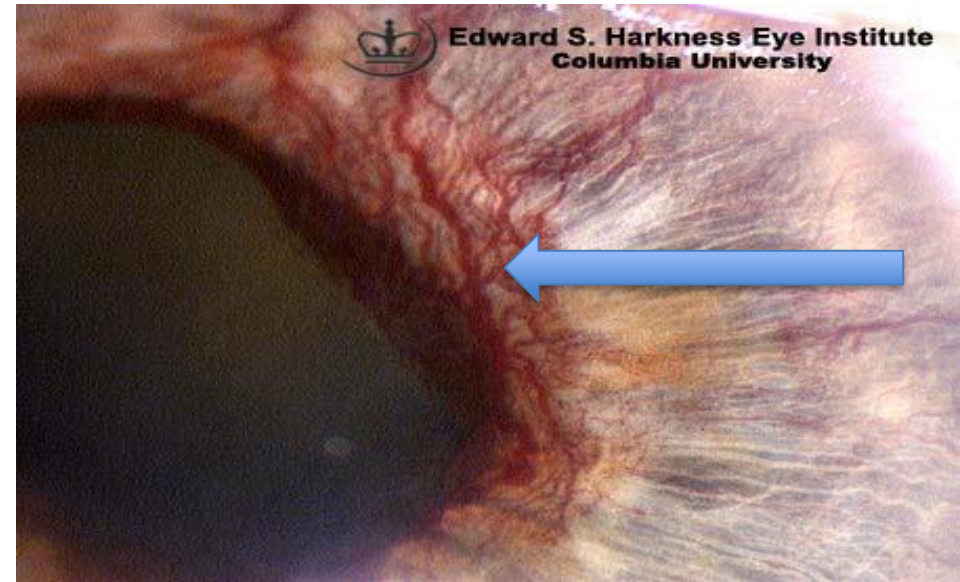
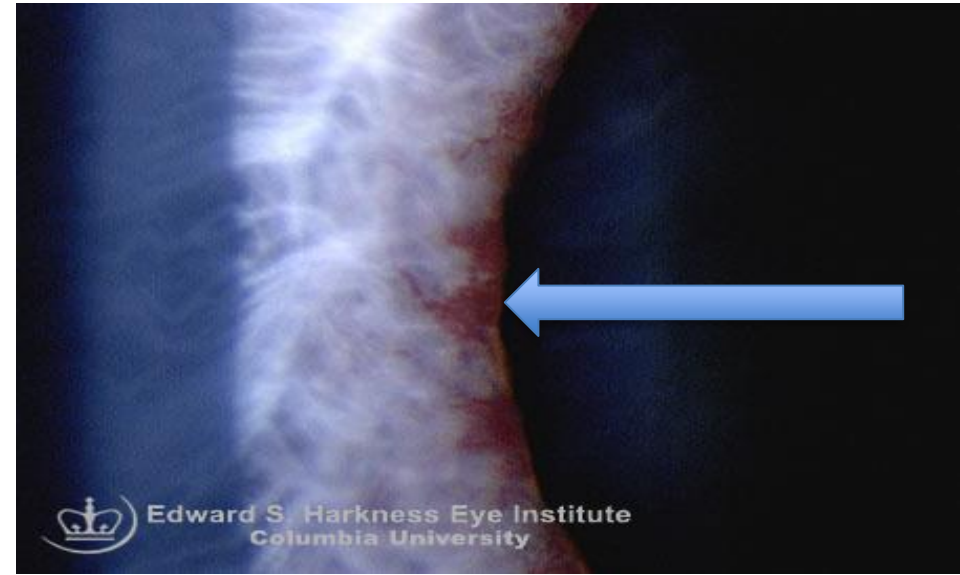
Secondary Glaucomas

- Secondary glaucoma associated with ophthalmic disorders:
 - Neovascular glaucoma (NVG)
 - Pigment dispersion syndrome (PDS)/glaucoma (PDSG)
 - Pseudoexfoliation syndrome (PXF)/glaucoma (PXG)
 - Lens induced glaucoma
 - Phacolytic
 - Phacomorphic
- Secondary glaucoma associated with trauma:
 - Angle recession glaucoma
- Secondary glaucoma associated with inflammation:
 - Uveitic glaucoma
 - Fuchs Heterochromia
 - Glaucomatocyclitic crisis

Neovascular Glaucoma (NVG)

Iris Neovascularization

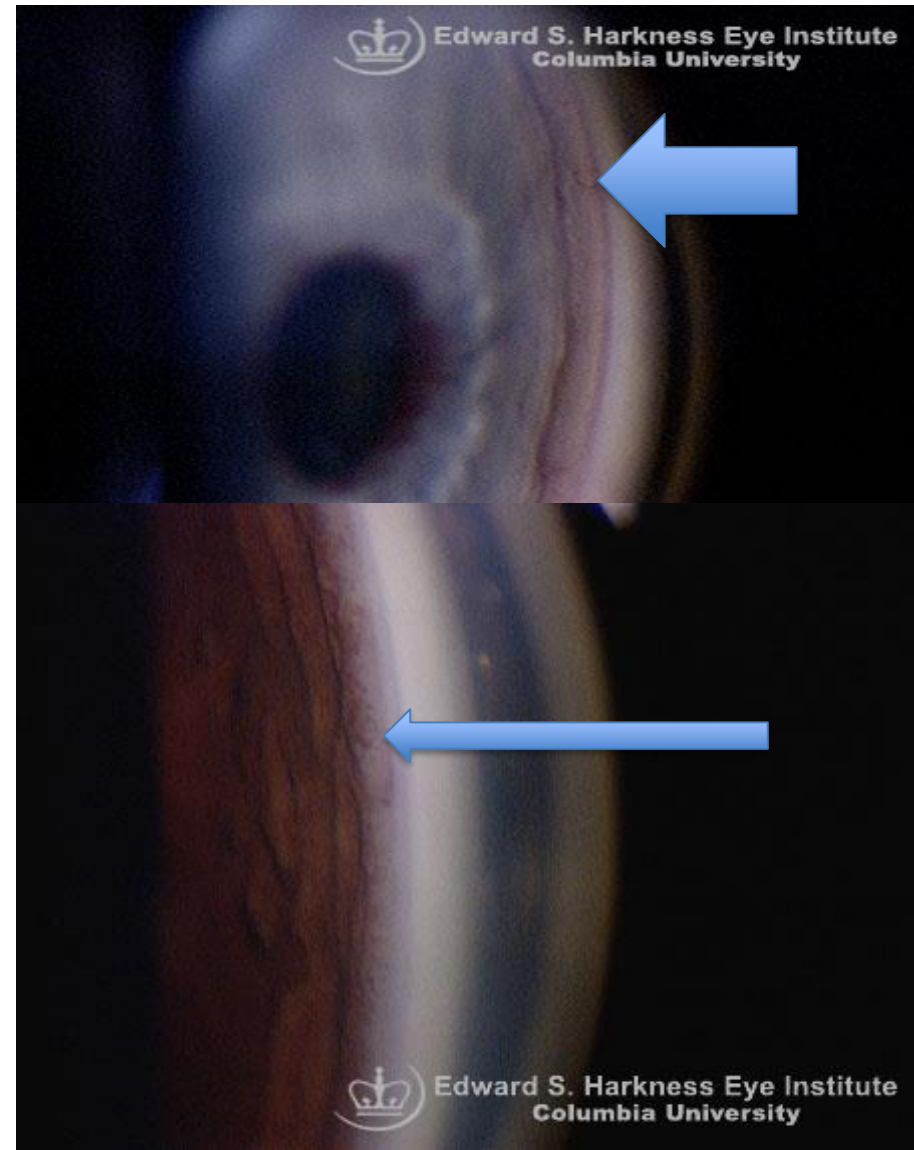
- New vessel growth usually begins at the pupil margin
 - enlarge, and grow in an irregular pattern along the iris surface



Angle Neovascularization

- New vessels grow to anterior chamber angle
 - new blood vessel growth brings along fibrovascular tissue
 - causes a reduction of aqueous humor outflow

<http://dro.hs.columbia.edu/nvg.htm>



Peripheral Anterior Synechiae (PAS)

- If the membrane contracts it pulls the peripheral iris into the TM leading to the formation of PAS

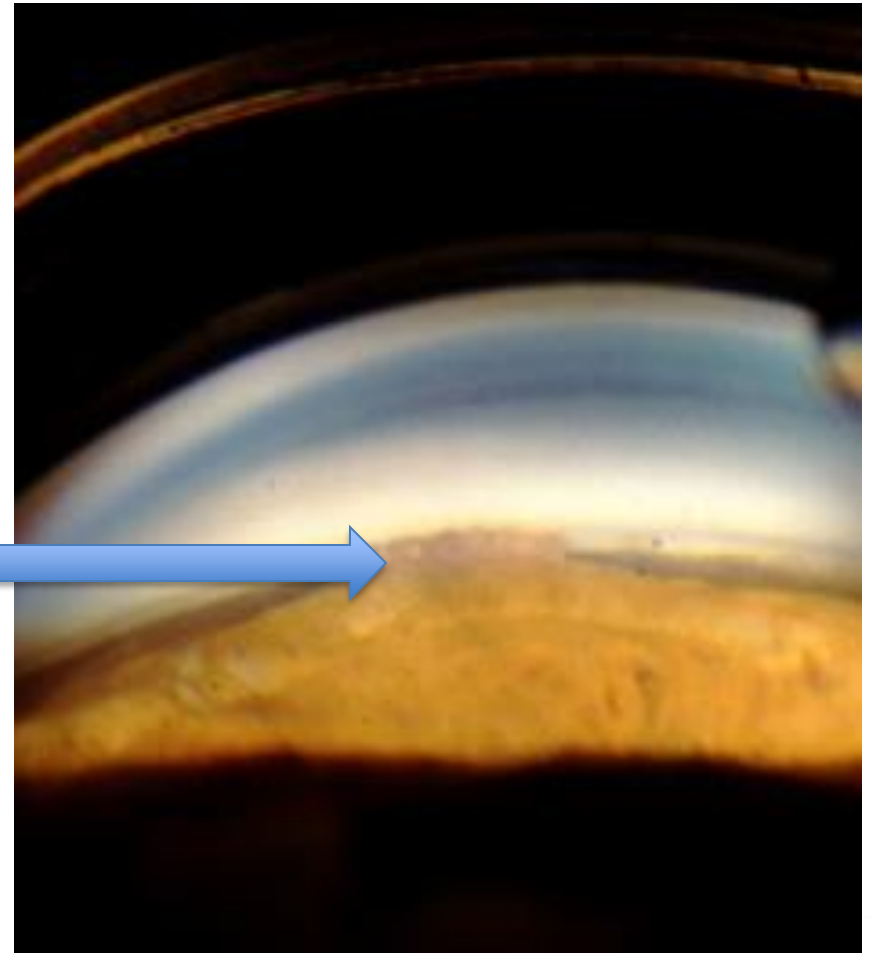
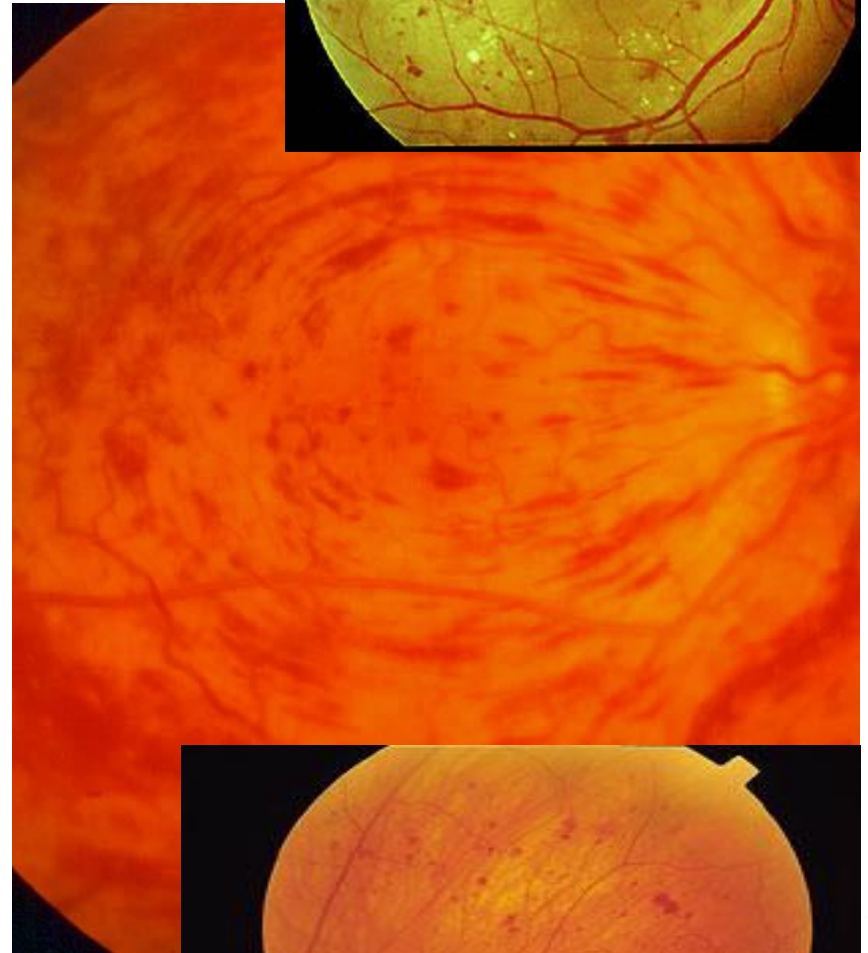
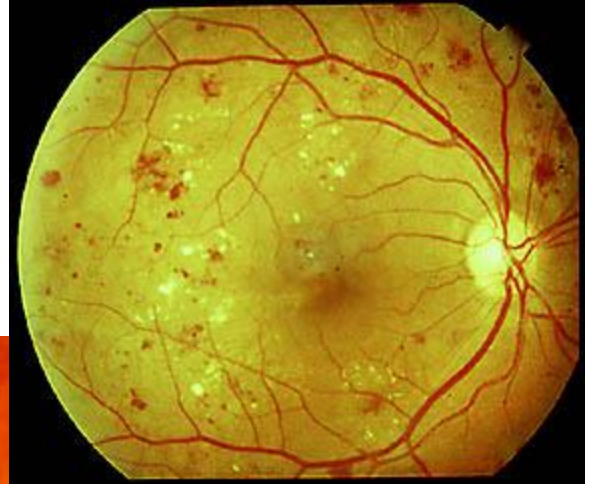

Image courtesy: John McSoley, OD

NVG: Etiology

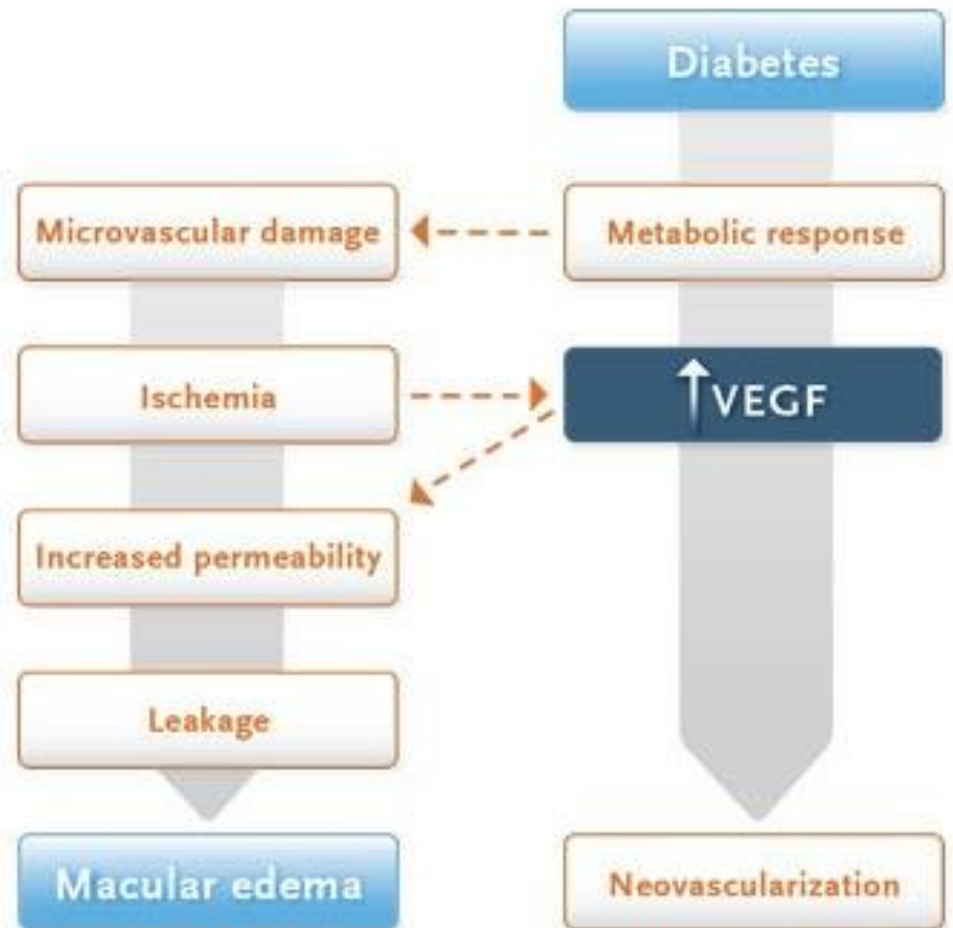
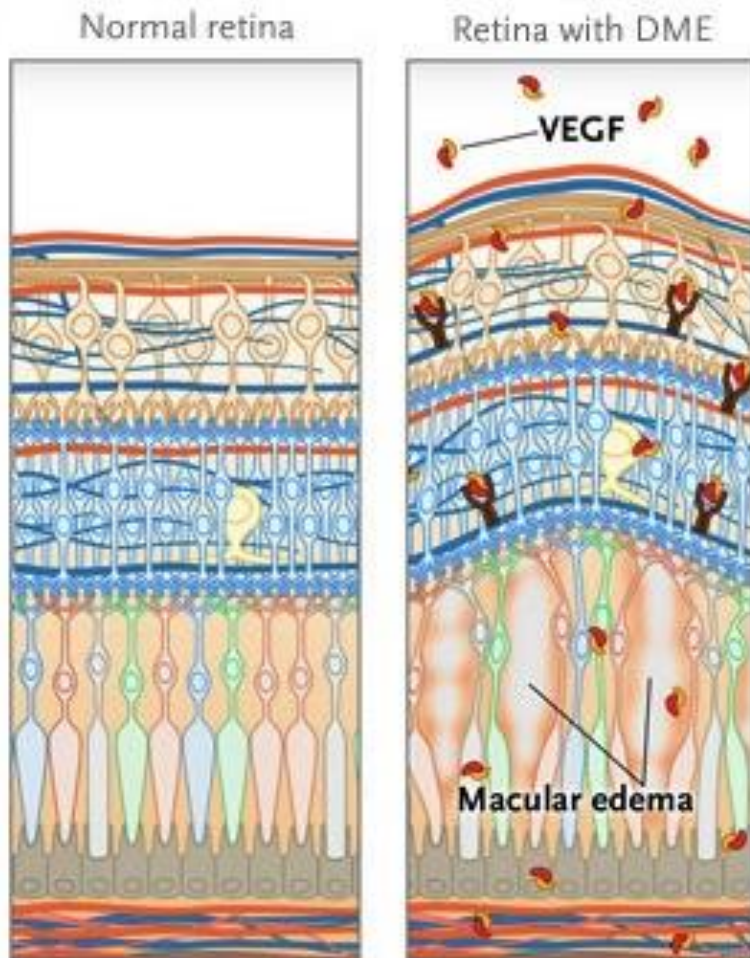
- Ocular ischemic disorders account for 97% of cases with NVG
 - The most common disorders leading to NVG are:
 - diabetes mellitus,
 - CRVO, and
 - ocular ischemic syndrome.



NVG and VEGF

- There is adequate evidence supporting the role of VEGF-A in the pathogenesis of ocular neovascularization,
 - studies have confirmed the increased levels of VEGF-A in glaucoma and NVG in particular
 - experimental elevation of VEGF-A levels induces typical neovascularization

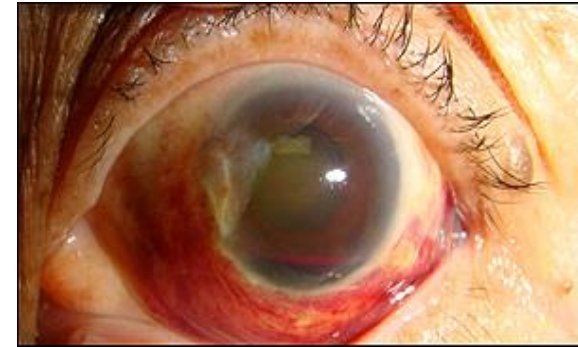VEGF and Diabetes



Case

- A 68-year-old woman with a history of poorly controlled diabetes presents with poor vision of the left eye for about 2 months.
- She notes an episode of left eye pain 2 months ago that lasted for a week

Case Presentation



	OD	OS
VA	20/40	20/800
Pupils	No APD	Mild APD
SLE	Cornea clear No NVI Angle Open 2+ NS	Extensive NVI with angle synechiae 20% hyphema 4+ NS
IOP	18 mm Hg	44 mm Hg
Fundus	PDR with NVD and NVE Focal area of subhyaloid hemorrhage	PDR with NVD and NVE Focal area of subhyaloid hemorrhage
C/D	0.4	0.7

NVG: Management

- Treatment of the underlying disease and control of IOP.
- The key to NVG management lies in elimination of the angiogenic stimulus
- Effective treatments for retinal ischemia include:
 - Panretinal photocoagulation (PRP),
 - cryotherapy, and
 - endolaser treatment combined with vitrectomy.
- Despite the reduction of retinal ischemia and additional antiglaucoma medication
 - NVG frequently exhibits irreversible intraocular pressure (IOP) elevation.

NVG: Medical Management

- Medical therapy is beneficial in lowering the IOP and include:
 - topical β -blockers,
 - α -2 agonists, and
 - topical or oral carbonic inhibitors
- Miotics (pilocarpine) and epinephrine drugs are contraindicated:
 - they may increase inflammation (increase permeability of the blood-aqueous barrier),
 - cause miosis, and
 - worsen synechial angle closure

NVG: Medical Management

- Topical prostaglandins are generally not used because they too can exacerbate inflammation
- Intraocular inflammation may be treated with topical corticosteroids.

NVG: Anti-VEGF

- New treatment includes the use of anti-VEGF
 - several studies have shown that specific inhibition of VEGF-A inhibits pathologic neovascularization in the iris, choroid, cornea, and retina
- The 3 traditional anti-VEGF-A agents available for clinical use are:
 - Bevacizumab (Avastin),
 - Ranibizumab (Lucentis), and
 - Pegaptanib (Macugen).
- Most recent addition is:
 - **Aflibercept (VEGF-TRAP) (Eyelea)**

NVG: Anti-VEGF

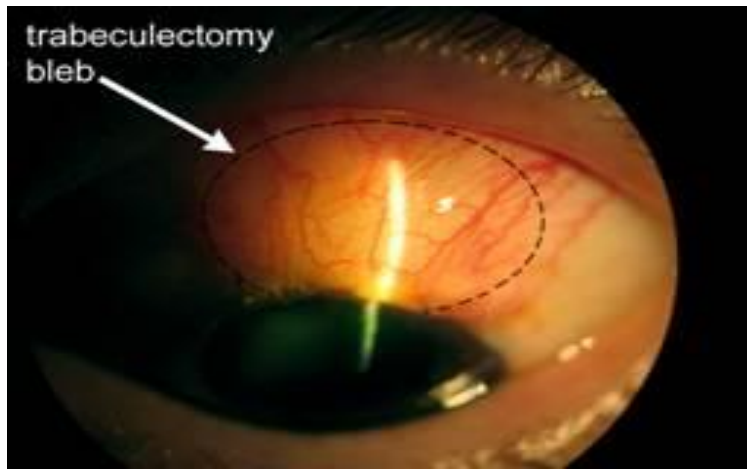
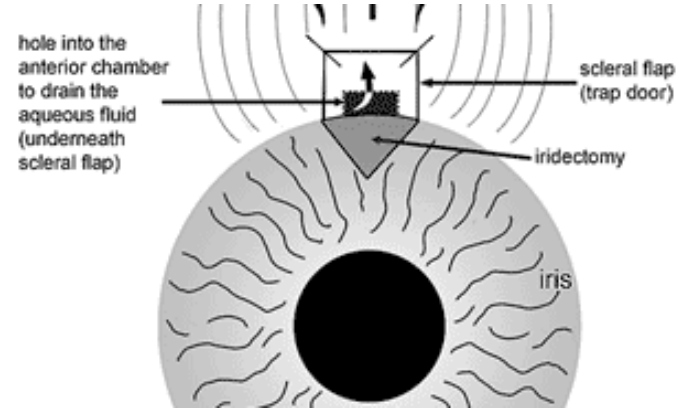
- Intra-vitreous anti-VEGF has been shown effective in regression of new vessels and reduction of IOP in NVG
 - regression occurs quickly, often within 1 week.
 - however, bevacizumab's duration of action is short-lived, lasting about 4 weeks.
- The mechanism by which IOP may be reduced by bevacizumab or any other anti-VEGF-A agent is a matter of speculation

NVG: Glaucoma Surgery

- Glaucoma filtering surgery is now considered standard for the treatment of the elevated IOP in NVG patients
- Glaucoma surgery is indicated to optimally control IOP if medical therapy has proven to be inadequate. Includes procedures such as:
 - aqueous tube shunt surgery,
 - cyclodestruction, or
 - antimetabolite-enhanced filtration surgery.

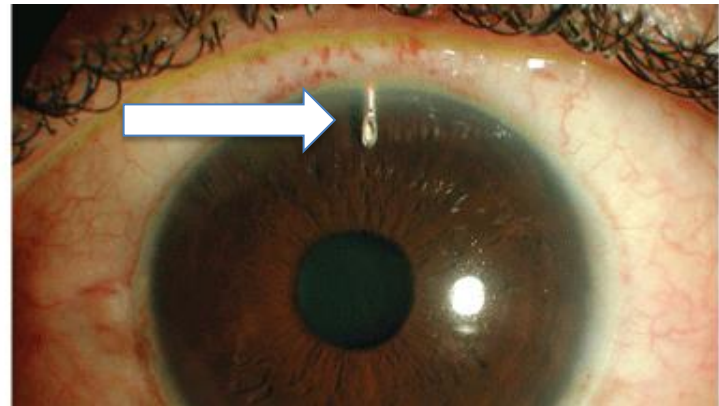
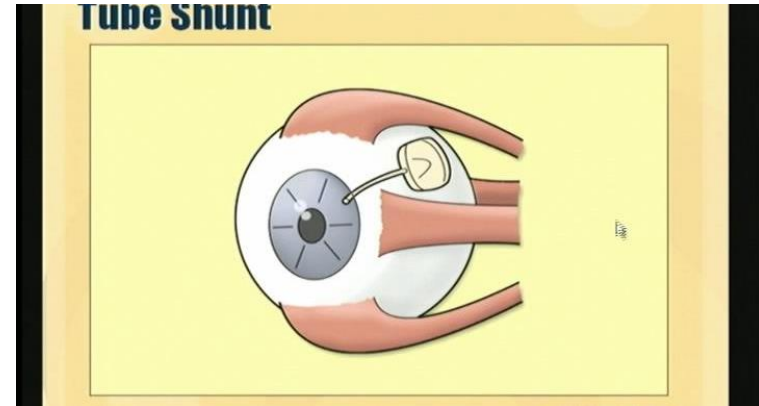
Trabeculectomy

- Trabeculectomy with and without mitomycin-C has been shown to be successful in controlling intraocular pressure
- The use of anti-metabolites improves IOP control and the success of trabeculectomy



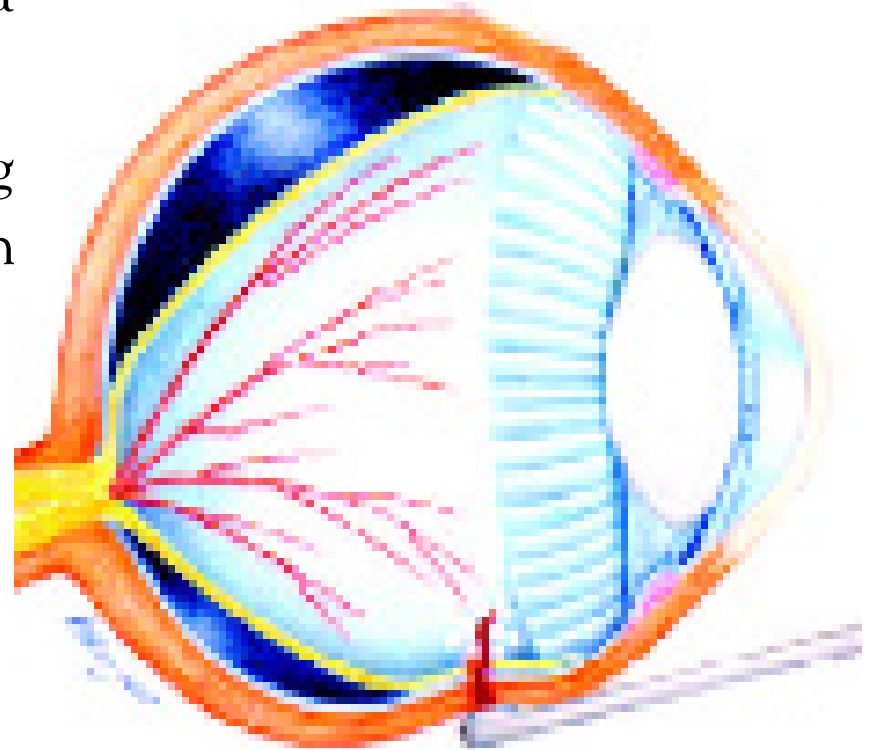
Glaucoma Drainage Implant

- implantation of a tube shunt
- most common treatment for glaucoma when medications have proven to be insufficient



Cyclodestructive Procedures

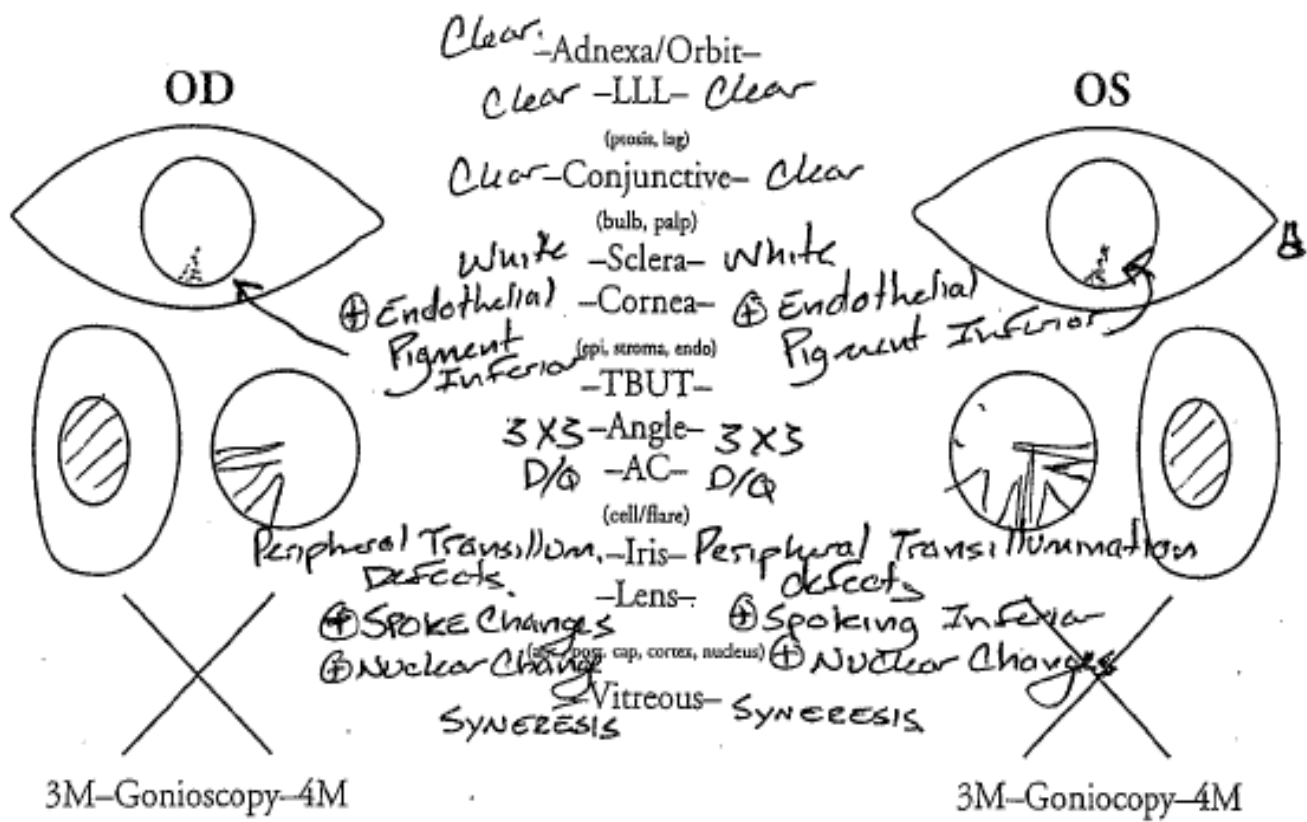
- Ablating a portion of the cilia body
 - IOP is lowered by decreasing aqueous humour production
- Destruction of the ciliary body by:
 - transscleral application of cryotherapy or
 - transscleral or endoscopic delivery of diode, krypton Nd:YAG laser.



NVG: End Stage

- For blind painful eyes with uncontrollable IOP, options include:
 - continued medical therapy,
 - cyclodestruction,
 - retrobulbar alcohol injection, or
 - enucleation.

CASE



BP 128/72

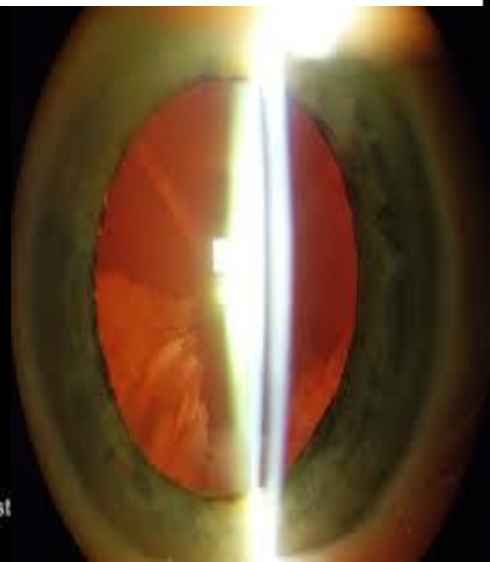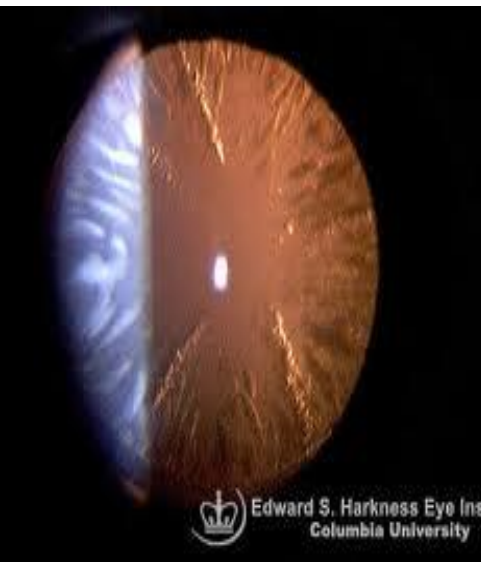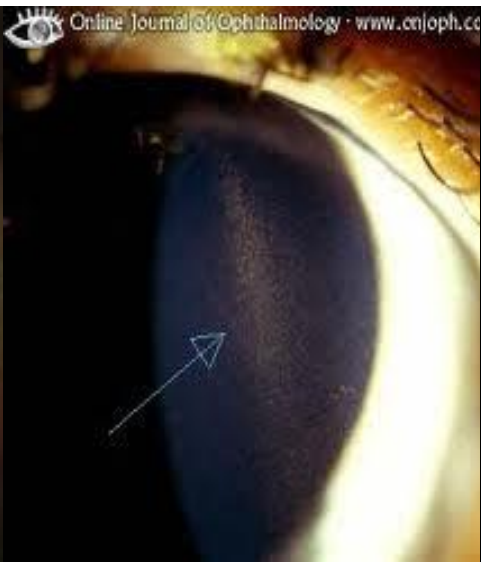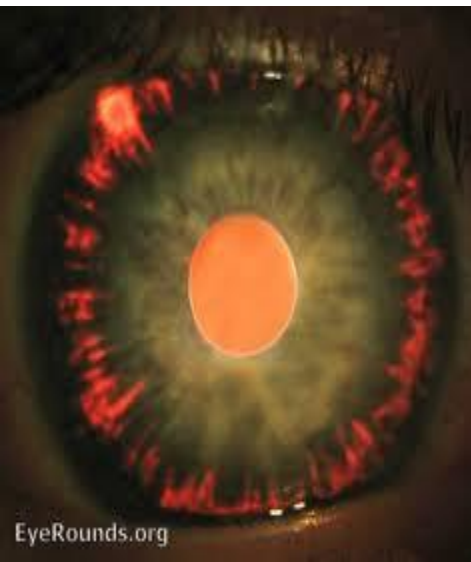
Tonometry Time 11:20 am

OD 26 mmHg (TAG) NCI
 OS 28 mmHg PEN

ANESTH. 1 g Fluox

Discussed side effects of dilation S.C.

Dilated:	Lenses:
M 5%, 1%	20D
N 2.5%, 10%	30D
C 1%	78D
OD OS <u>OU</u>	3 Mirror
time: <u>11:25 am</u>	Indent extended oph.



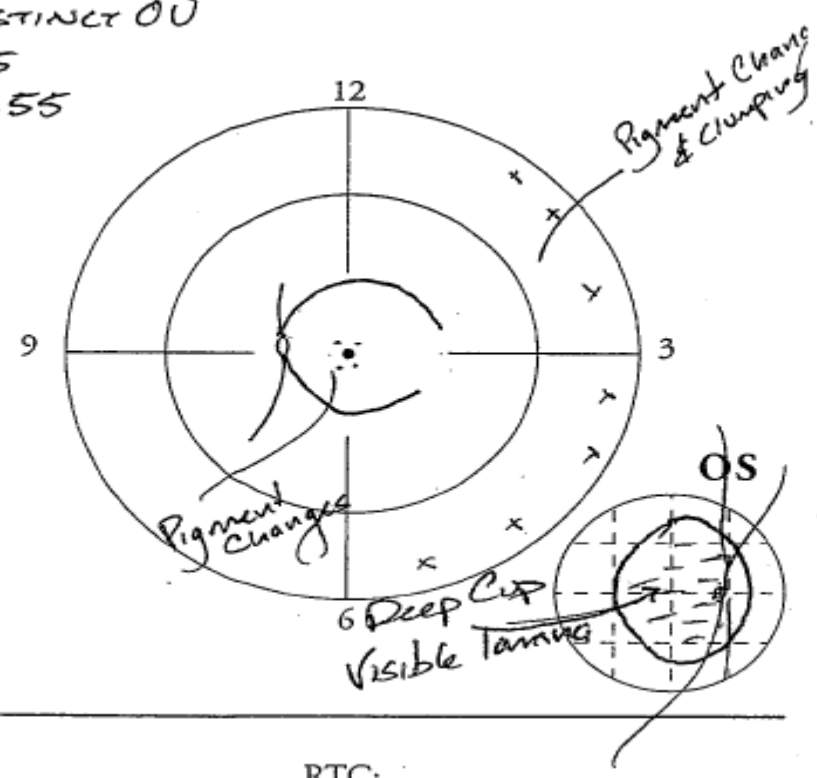

FLAT PINK, DISTINCT OU

.75 .75
.55+ .55

DISC
(size, color, NFL)
C/D

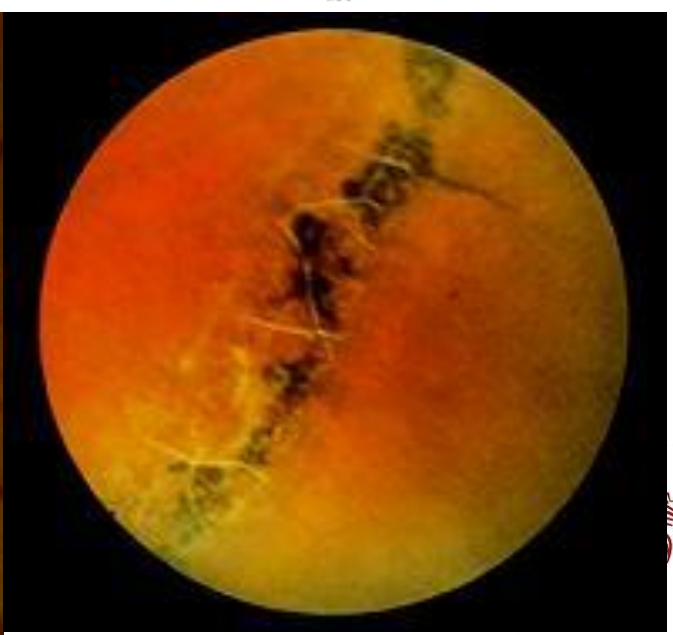
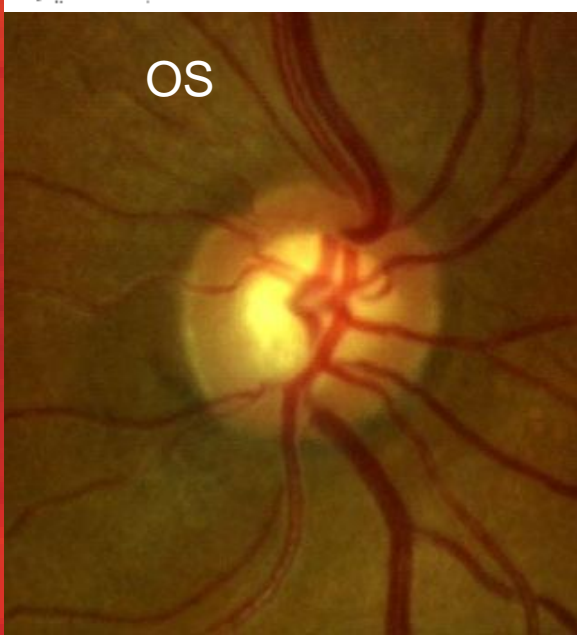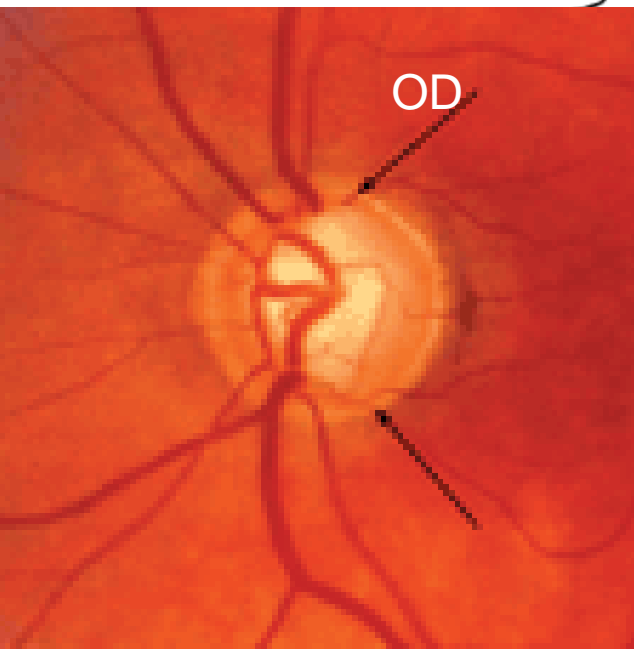
VESSELS
- SVP -
2/3 A/V 2/3
1/3 ALR 1/3

MACULA
- FLR -
PERIPHERY

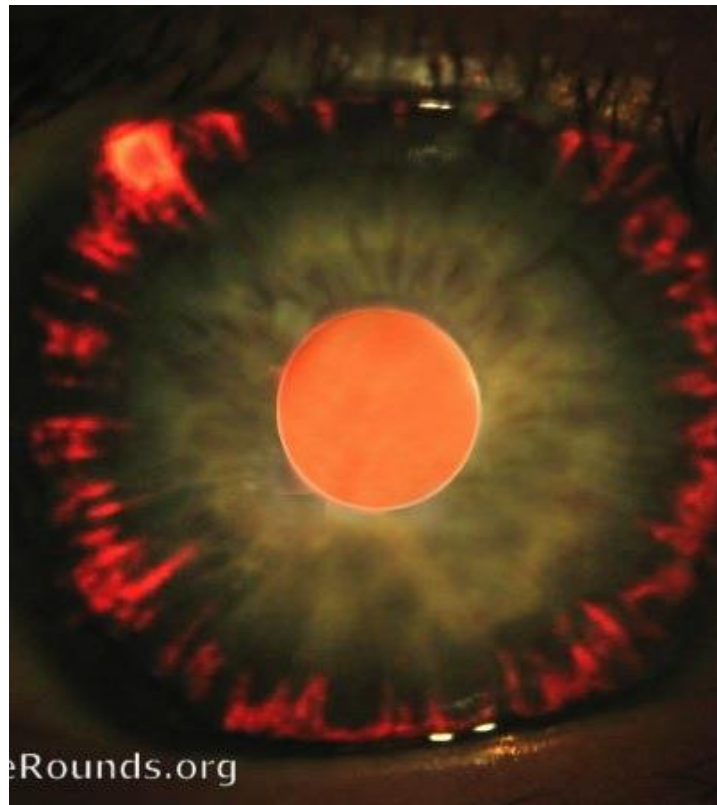


Dx: _____
Vessel Barring

RTC: _____



Pigment Dispersion Syndrome (PDS) and Pigment Dispersion Glaucoma (PDG)



Pigment Dispersion Syndrome: PDS

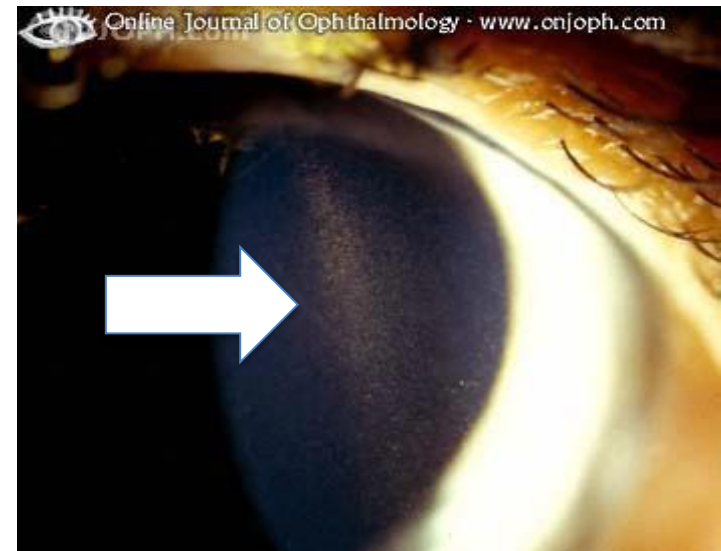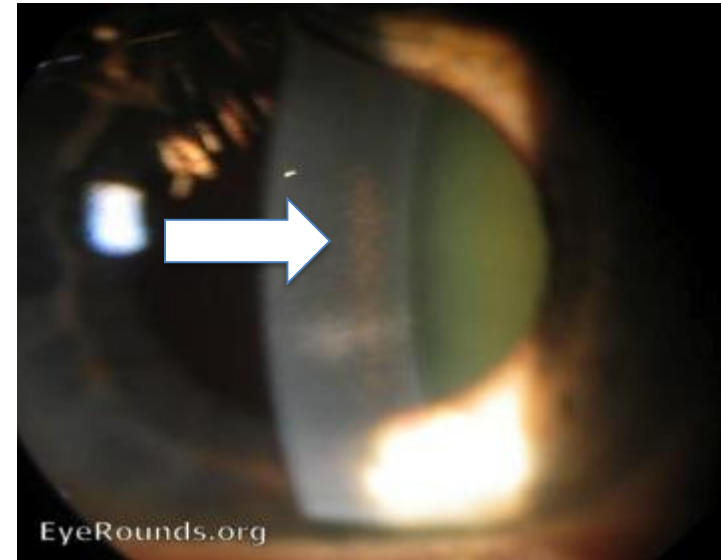
- The typical patient with PDS is:
 - young (20–40 years) and
 - myopic
- The US prevalence of PDS has been estimated to be approximately 2.5%
 - prevalence in non-Caucasians is thought to be low and may be a result of different iris anatomy or different behavior of the iris in non-Caucasians

Pigment Dispersion Syndrome: PDS

- tends to affect men and women in roughly equal numbers, although there might be a slight male preponderance with 58–67% of PDS patients being male in some reports
 - however, 78–93% of PDG patients are male

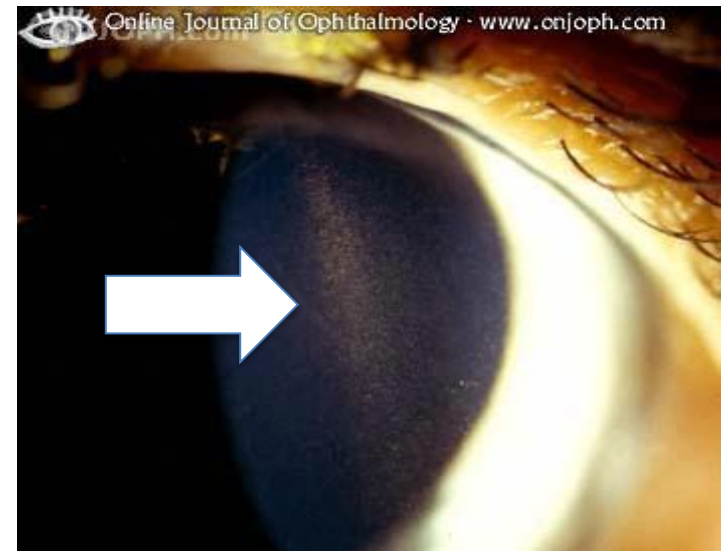
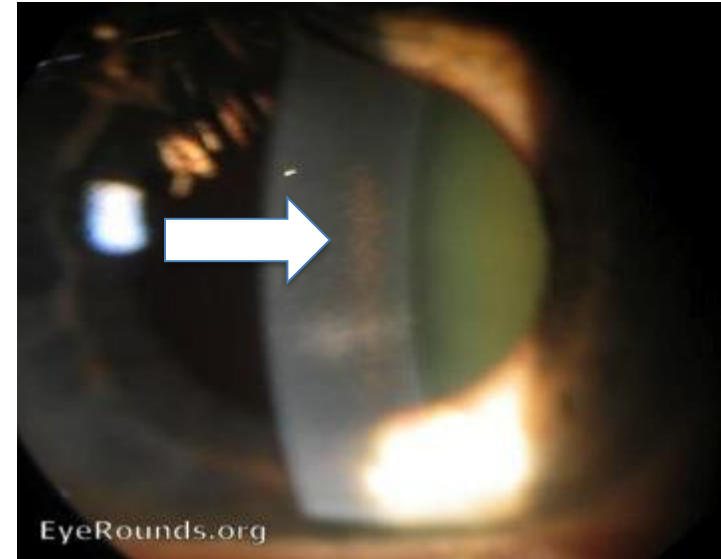
PDS Clinical Features

- *Krukenberg spindles*
 - The Krukenberg spindle refers to pigment deposition on the corneal endothelial surface that typically occurs in a vertical spindle-shaped pattern.
 - characteristic pattern is thought to occur secondary to aqueous convection currents within the anterior chamber



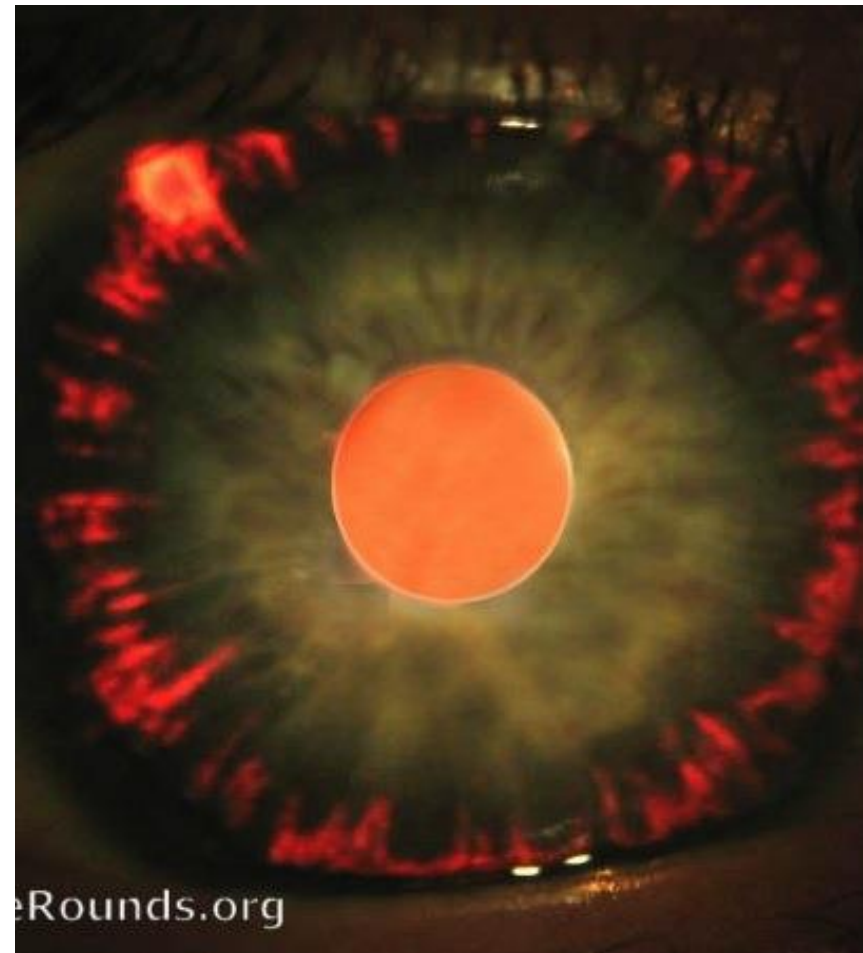
PDS Clinical Features

- *Krukenberg spindles*
 - not always present in PDS and are not pathognomonic of PDS.
 - presence of a Krukenberg spindle has been found to be more common in PDG



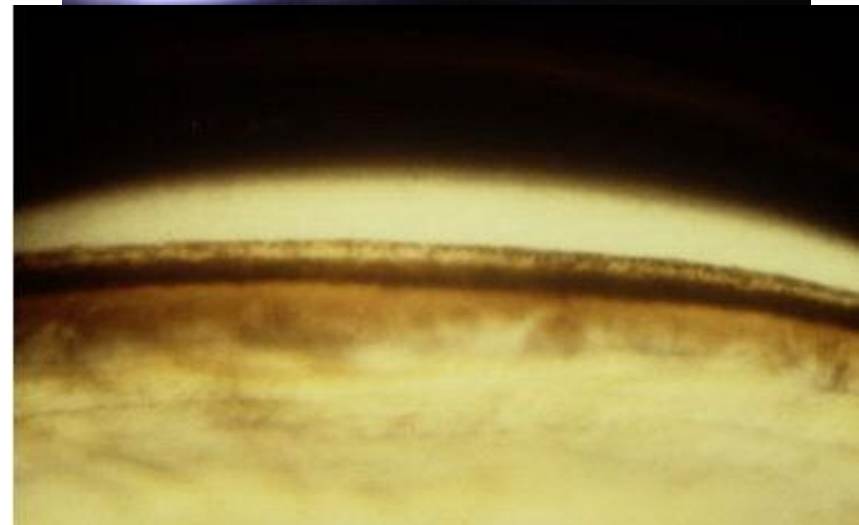
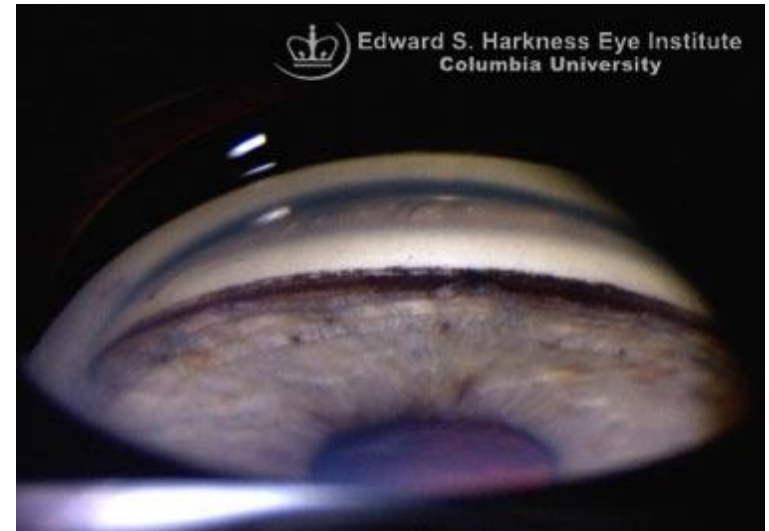
PDS Clinical Features

- Iris trans-illumination defects:
 - not always present in PDS eyes, but are present in most (86%) cases
 - more obvious in light-colored eyes.
 - PDS trans-illumination defects are commonly located in the mid-peripheral iris and occur with a spoke-like pattern



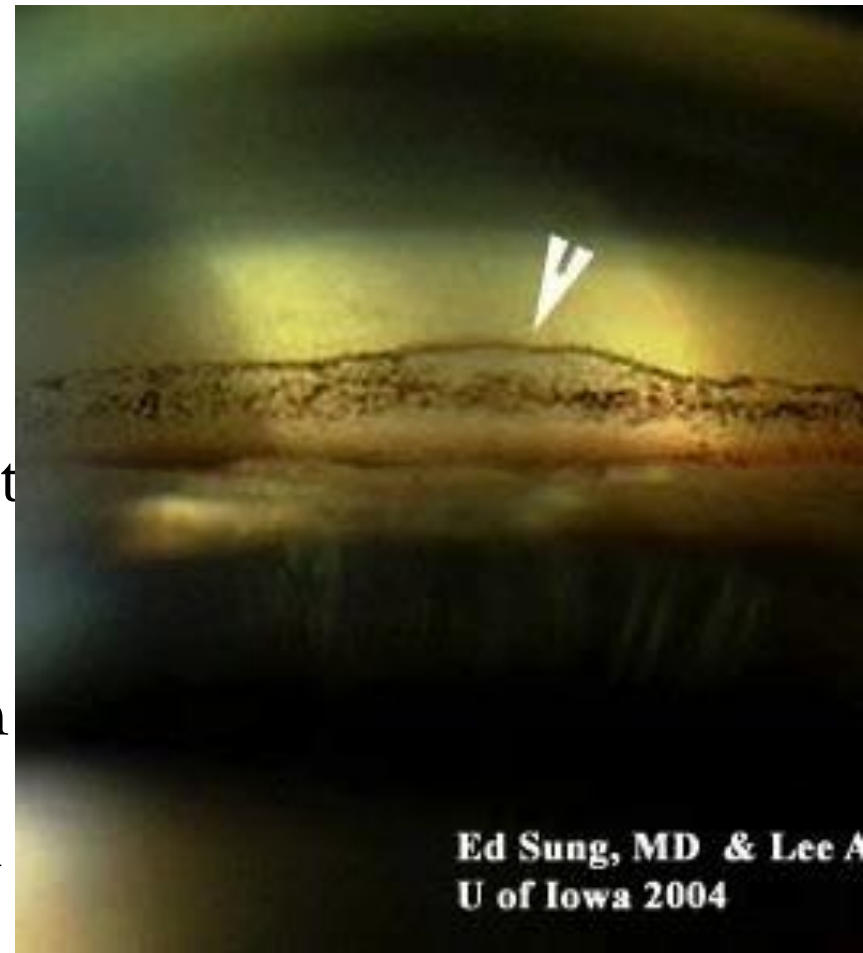
PDS Clinical Features

- Gonioscopy:
 - The characteristic gonioscopic feature is the increased TM pigmentation tends to be homogenous
 - in contrast to the patchy involvement in PXF syndrome
 - The full circumference of the TM tends to be affected, although pigmentation is more prominent inferiorly
 - possibly owing to gravity.



PDS Clinical Features

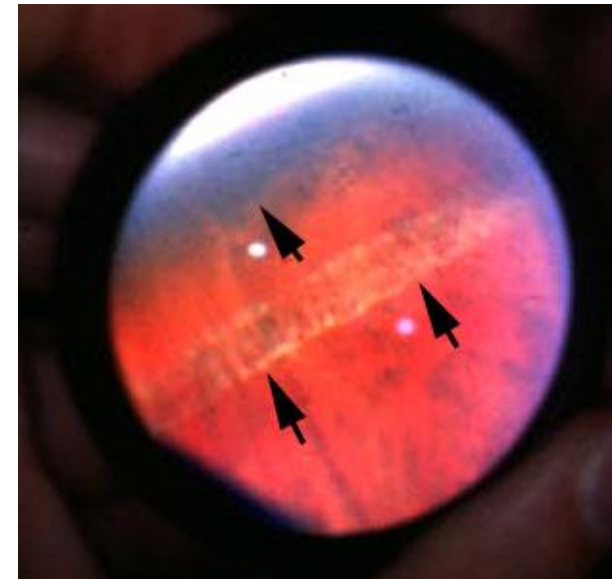- Gonioscopy:
 - Histologically, the melanin is located within the TM cells indicative of their phagocytic properties
- Pigment deposition also occurs at Schwalbe's line
 - producing a thin, dark line similar to Sampaolesi's line in PXF syndrome.
 - tends to be more prominently pigmented inferiorly.



Ed Sung, MD & Lee A
U of Iowa 2004

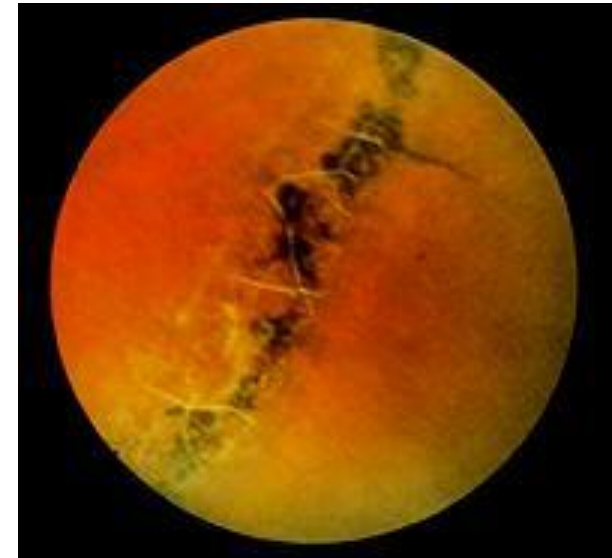
PDS Clinical Features

- *Posterior segment*
 - Lattice degeneration occurs in 8-11% of the general population
 - The incidence of atrophic holes in lattice degeneration ranges from 18-42%
 - Lattice retinal degeneration has been reported to be evident in 20-33% of cases of PDS and PDG
 - greater than would be expected for the associated myopia



PDS Clinical Features

- *Posterior segment*
 - retinal breaks occur more frequently than in normal eyes, affecting 12% of eyes with PDS and PDG
 - risk of retinal detachment is only 0.1-0.7% in the “normal” phakic eye
 - retinal detachments have been reported to occur in 5.5–6.6% of PDS cases
 - higher than expected for the degree of myopia and is independent of miotic use



Pigment Dispersion Glaucoma (PDG)

- The typical PDG patient is young (30–50 years) and myopic
 - degree of myopia in groups of PDS patients that develop PDG is higher than those who do not develop PDG
- Unlike PDS, PDG is much more prevalent in men, with 78–93% of PG patients being male
 - tends to occur at an earlier age in men, at 34–46 years, whereas women tend to develop PDG a decade or so later at 43–53 years of age
 - in addition to occurring earlier in men, PDG tends to be more aggressive in men than women

PDS/PDG Conversion

- Estimates of the proportion of patients with PDS that have PDG have ranged from 6% to 43%
 - large degree of variation that reflects widely differing study inclusion criteria
- It is generally considered that patients with PDS will develop PG (after diagnosis):
 - 5–10% at 5–6 years,
 - 15% at 15 years,
 - 35% developing PG at 35 years.

Pigment Dispersion Glaucoma (PDG)

- *IOP*
 - PDG tends to be a high-tension type of glaucoma with a mean IOP of 29 mmHg at diagnosis
 - in one long-term analysis
 - 25% of the patients had an IOP >31 mmHg at diagnosis, with 12.5% having an IOP of >39 mmHg
 - there is a tendency for the glaucoma to ‘burn-out’ with increasing age, with target IOPs becoming progressively easier to reach.

Pigment Dispersion Glaucoma (PDG)

- IOP
 - the presence of OH (IOP > 21 mmHg) at the initial diagnosis of PDS has been identified as the most important factor for conversion to PDG
 - Siddiqui found that each 1 mmHg rise in IOP increased the risk of conversion from PDS to PG by a factor of 1.4

Pigment Dispersion Glaucoma (PDG)

- In normal eyes and those with POAG, exercise usually lowers IOP
 - In PDS/PDG, however, exercise induces pigment dispersion that may result in reduced aqueous outflow and significant IOP elevation
- Laser peripheral iridotomy (LPI) can prevent the exercise-induced phenomenon by relieving reverse-pupillary block and preventing posterior bowing of the iris
- the exercise-induced IOP elevation can be inhibited pharmacologically with pilocarpine, but not with b-blockers

Pigment Dispersion Glaucoma (PDG)

- *Visual field defects*
 - visual field progression has been reported to be common in PDG
 - 28-44% of cases progressing in 11-17 years
 - perhaps a reflection of the degree of IOP elevation
- In asymmetric cases of PDG
 - the glaucoma has been found to be more severe in the eye with the greater degree of pigment dispersion
 - the degree of TM pigmentation has been reported to correlate with severity, but the degree of trabecular pigmentation at presentation of PDS is not necessarily a predictor of conversion to PDG.

PDG: Treatment

- **Pilocarpine**

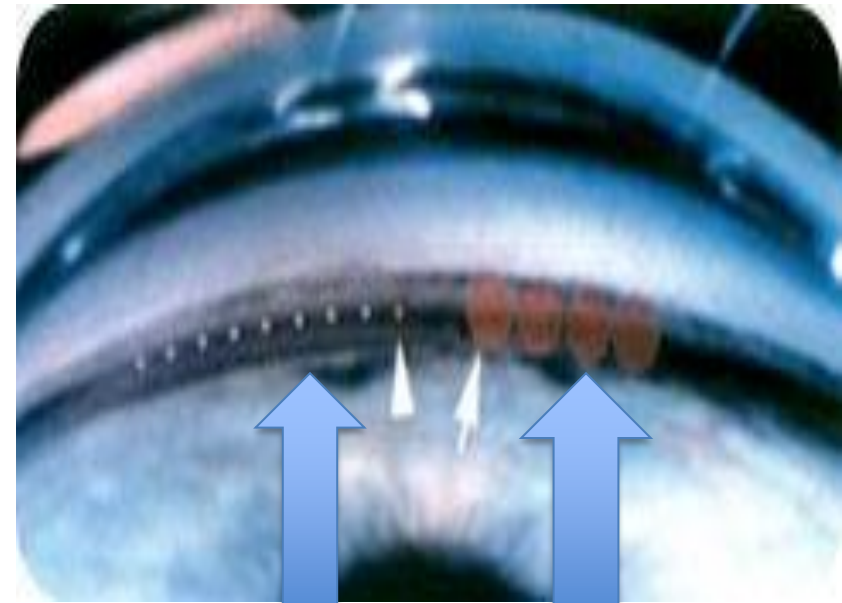
- Pilocarpine is almost an ideal therapy for PDG.
- Pilocarpine lowers IOP, prevents pupil dilation, reverses posterior iris bowing and inhibits exercise-induced rises in IOP, probably as a result of the drug-induced change in iris configuration
- However, pilocarpine has a poor side effect profile (accommodative spasm, increased risk of retinal detachment, cataract formation and systemic parasympathomimetic side-effects, such as dry mouth).

PDG: Treatment

- Prostaglandin analogues are potent ocular hypotensive agents, but have no specific anti-PDS effects.
- The enhancement of uveoscleral outflow may be beneficial in PDS/PDG patients and latanoprost has been shown to be more effective in reducing IOP in PDG patients than timolol
- Increased iris pigmentation occurs with prostaglandin analogues, but this does not lead to increased pigment dispersion as it primarily affects the iris stromal melanocytes and not the iris pigment epithelium
- Thus, prostaglandin analogues are not contraindicated in PG and in clinical practice are often used as first-line agents.

PDG: Treatment

- Argon laser trabeculoplasty (ALT) has been shown to be particularly effective in PDG
 - success may be due to the greater energy absorption by the pigmented TM.
 - ALT in young PDG patients seems to be more effective than in older patients, unlike with POAG
 - the success of ALT diminishes with time, with a reported success rate of only 45% at 6 years



ALT

SLT

PDG: Treatment

- A laser peripheral iridotomy (LPI) equalizes the pressure between the AC and the PC
 - relieving reverse-pupillary block, flattening the iris and reversing posterior iris bowing to prevent further pigment release.
- The advantageous effect of iridotomy was found to be more significant in patients <40 years
 - probably a reflection of the condition being more likely to be in an active phase in younger patients
- LPI alone is unlikely to be beneficial in eyes that already have permanent trabecular damage and/or progressive glaucoma because it does not in itself reduce IOP.

LPI and PDS/PDG Conversion

- Scott (2010) study suggests that there is no benefit o YAG LPI in preventing progression from PDS with OHT to PG within 3 years of follow-up.
 - suggest little benefit in performing the procedure in eyes with established OHT.
- However, patients with PDS, minimal trabecular meshwork damage, and no OHT may benefit from a procedure that reduces the dispersion of pigment.

Case

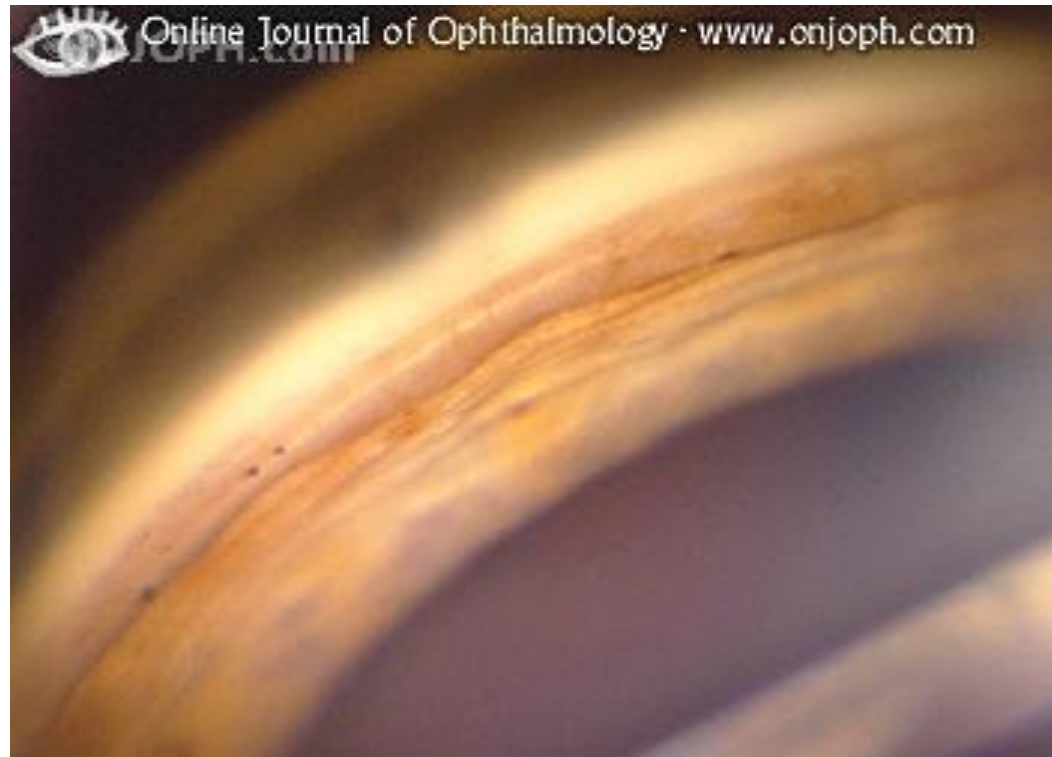
- 50 YR WM
- POHx: had cataract surgery in his left eye at age 25 secondary to trauma to the eye,
 - Has a mid-dilated pupil post trauma
- PMHx: no known health problems and no medications
- VA: 6/6 (20/20) OD, OS

Health Assessment

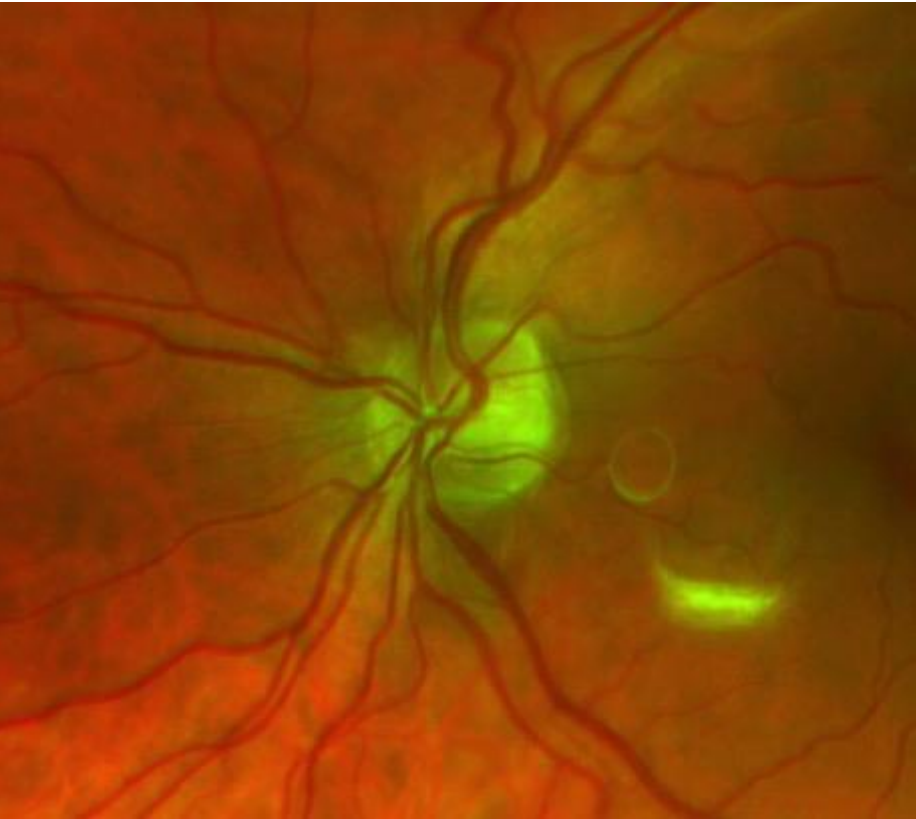- SLE:
 - OD unremarkable
 - OS: mid-dilated pupil with sluggish response to light
 - PCIOL well centered and no haze
- IOP: OD 12 and OS 26 mm Hg (TAG)
 - NCT OS (31 and 23)
 - Second visit: OD: 13 and OS: 27

Health Assessment

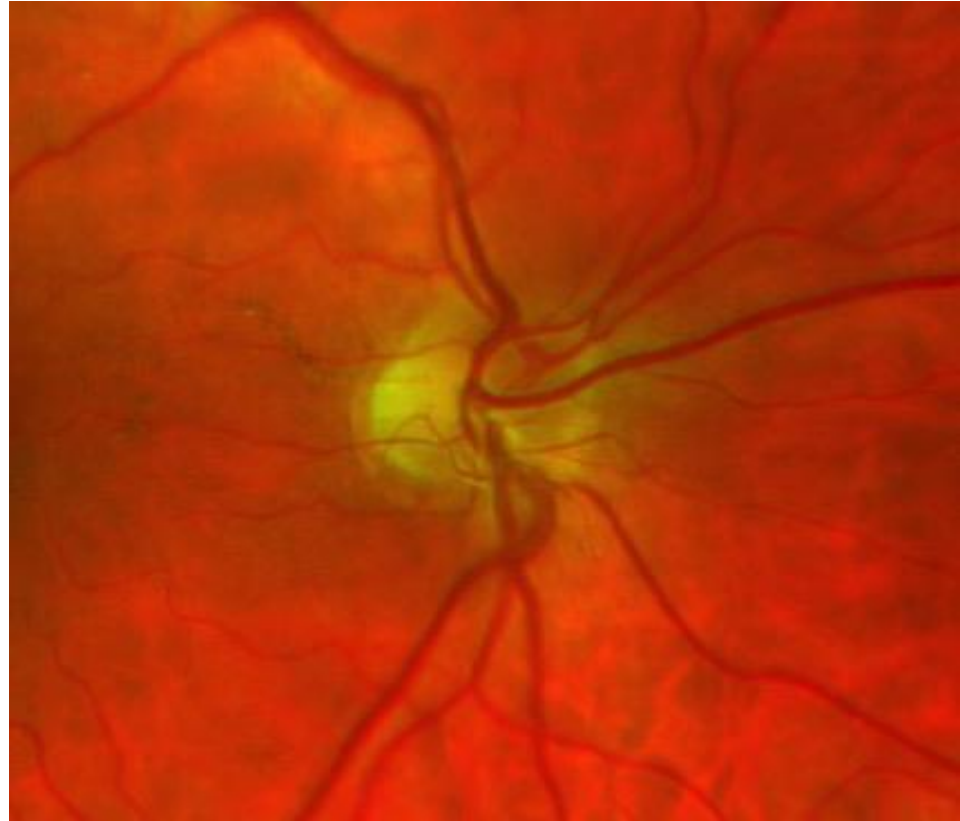- Gonioscopy:
 - OD: unremarkable
 - OS: see photo



Optic Nerves

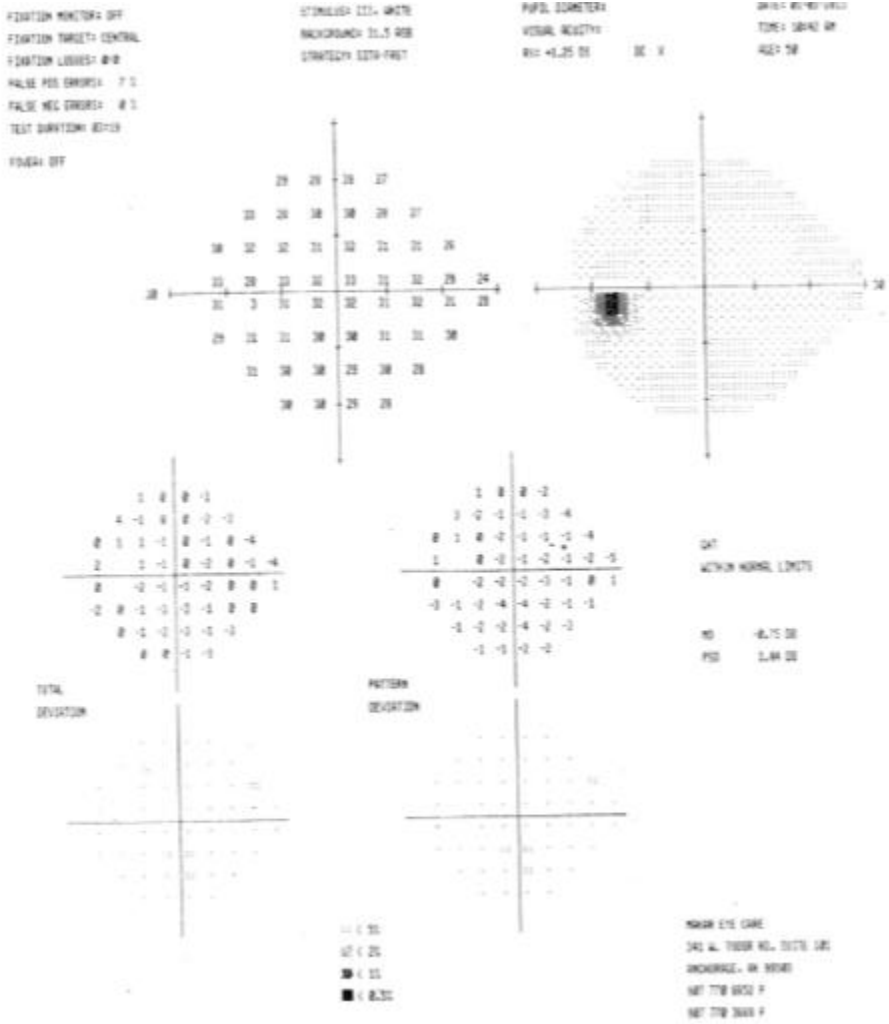


OS




OD

Visual Fields



OS

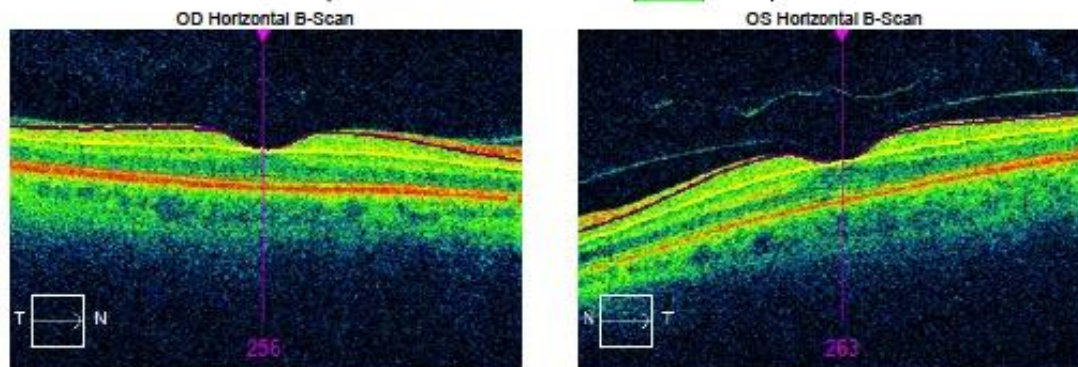
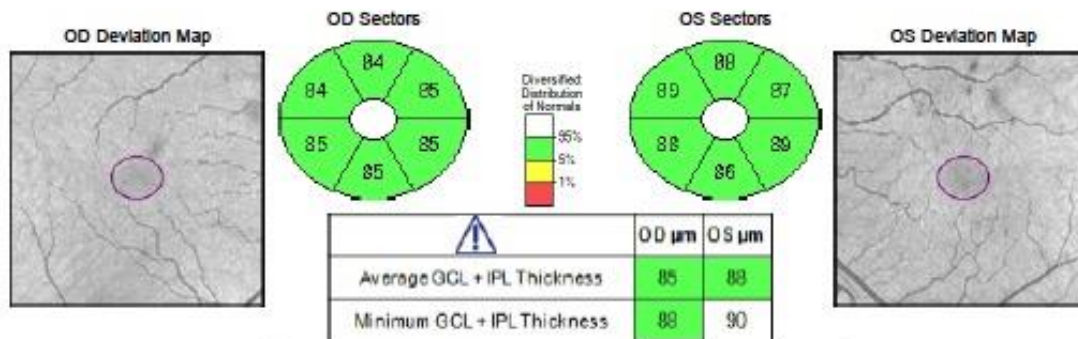
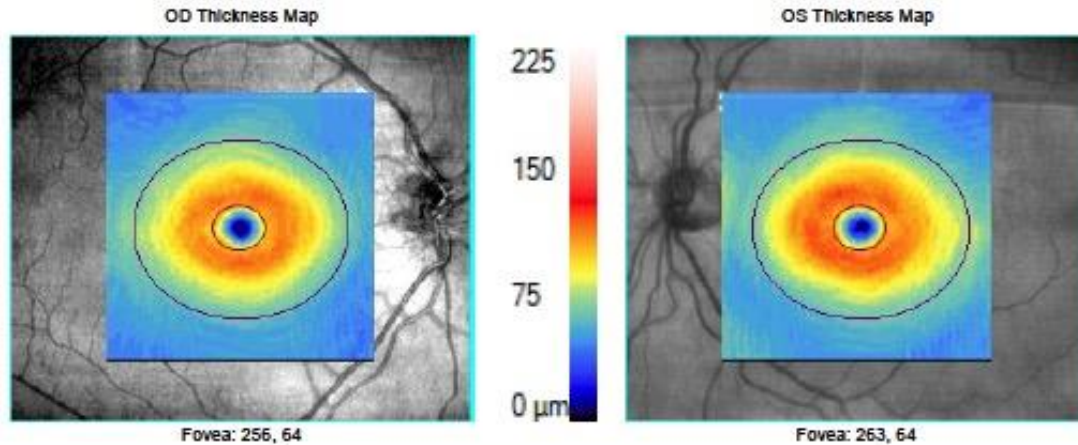


OD

Ganglion Cell Analysis

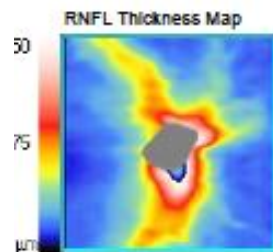
Ganglion Cell OU Analysis: Macular Cube 512x128

OD ● ● OS

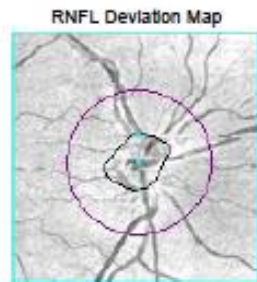
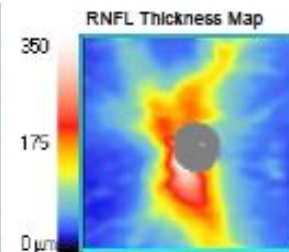


RNFL and ONH Analysis

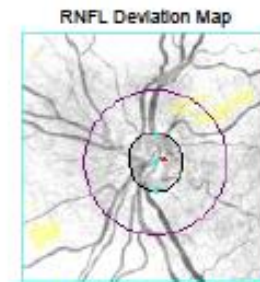
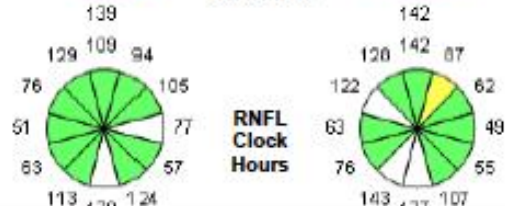
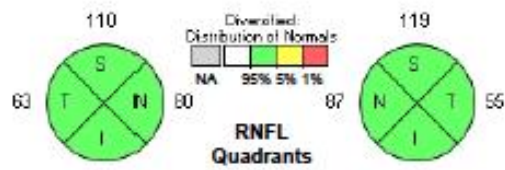
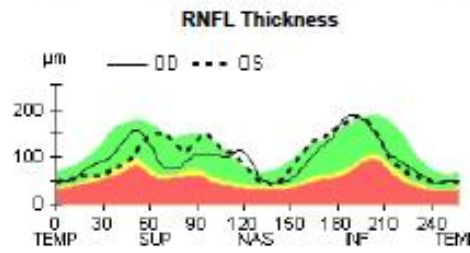
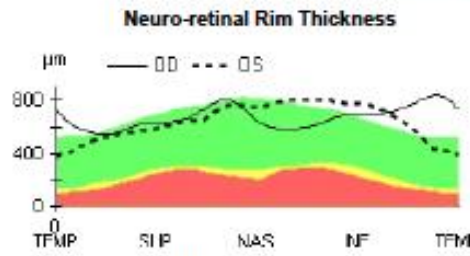
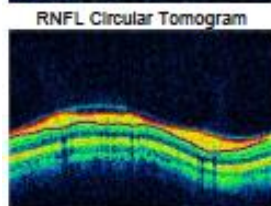
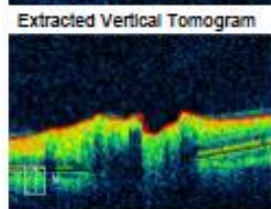
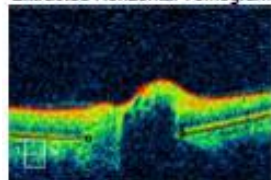
ONH and RNFL OU Analysis: Optic Disc Cube 200x200 OD ● ● OS



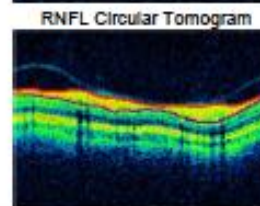
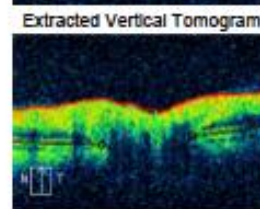
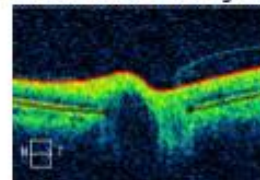
	OD	OS
Average RNFL Thickness	98 μm	101 μm
RNFL Symmetry	81%	
Rim Area	1.47 mm^2	1.46 mm^2
Disc Area	1.47 mm^2	1.47 mm^2
Average C/D Ratio	0.07	0.11
Vertical C/D Ratio	0.07	0.07
Cup Volume	0.000 mm^3	0.000 mm^3



Disc Center(0.03,-0.06)mm
Extracted Horizontal Tomogram



Disc Center(0.21,-0.06)mm
Extracted Horizontal Tomogram



ANGLE RECESSSION GLAUCOMA

Angle Recession

- investigators have reported that more than 60% of eyes with non-penetrating traumatic injuries will have some degree of angle recession.
- although traumatic angle recessions may occur without anterior chamber hemorrhage,
 - a strong correlation between hyphema and angle recession has been established.
- Careful gonioscopy has revealed that between 56% and 100% of patients with traumatic hyphema have some degree of angle recession

Angle Recession: Causes

- The most frequent cause of injury-inducing angle recession occurred as a result of:
 - sports or other recreational accidents
 - assault
 - Less common causes are:
 - automobile or industrial accidents,
 - projectiles from toy guns or slingshots, and
 - other leisure activities
 - A small percentage of people will deny any previous episode of ocular trauma despite the presence of obvious eyelid scars and pupillary sphincter tears.

Angle Recession Glaucoma

- Although recession of the iridocorneal angle is common after blunt trauma,
 - only 6% to 7% of these eyes will eventually develop glaucoma
- There appear to be two peak incidences of glaucoma after angle recession.
 - the first peak occurs within the first few weeks to years after the trauma, and
 - the second peak occurs 10 or more years after the injury

Angle Recession Glaucoma

- There is an association between the extent of angle recession and the development of glaucoma
- It appears that those eyes with less than 180 degrees of recession are unlikely to develop glaucoma
- whereas most investigators agree that patients with 180 to 360 degrees of angle recession will have a greater risk of developing late-occurring glaucoma

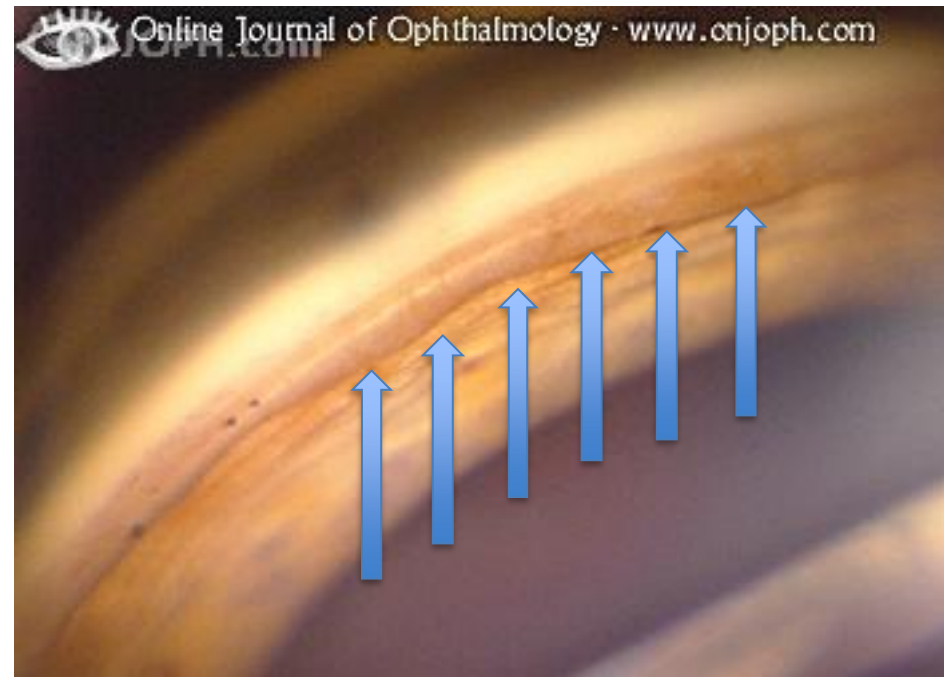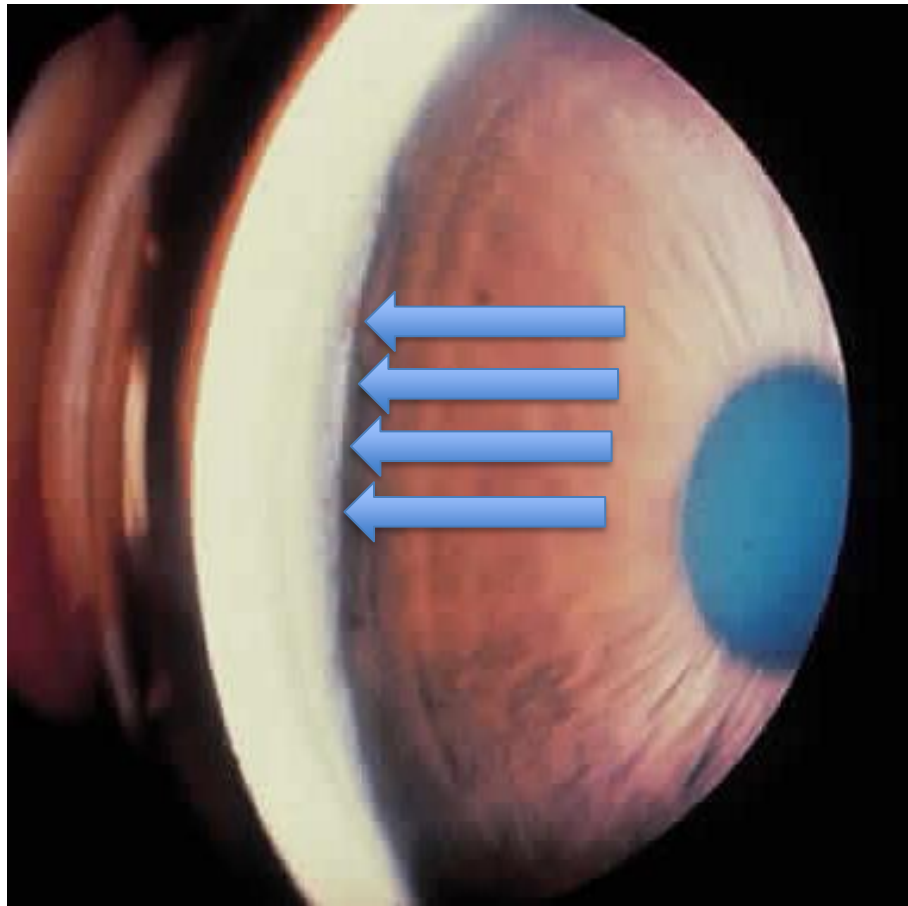
Angle Recession Glaucoma

- In eyes that do develop angle recession glaucoma:
 - the contralateral nontraumatized eye has been reported to have a 50% chance of developing open-angle glaucoma, sometimes years after the pressure rise was noted in the traumatized eye.

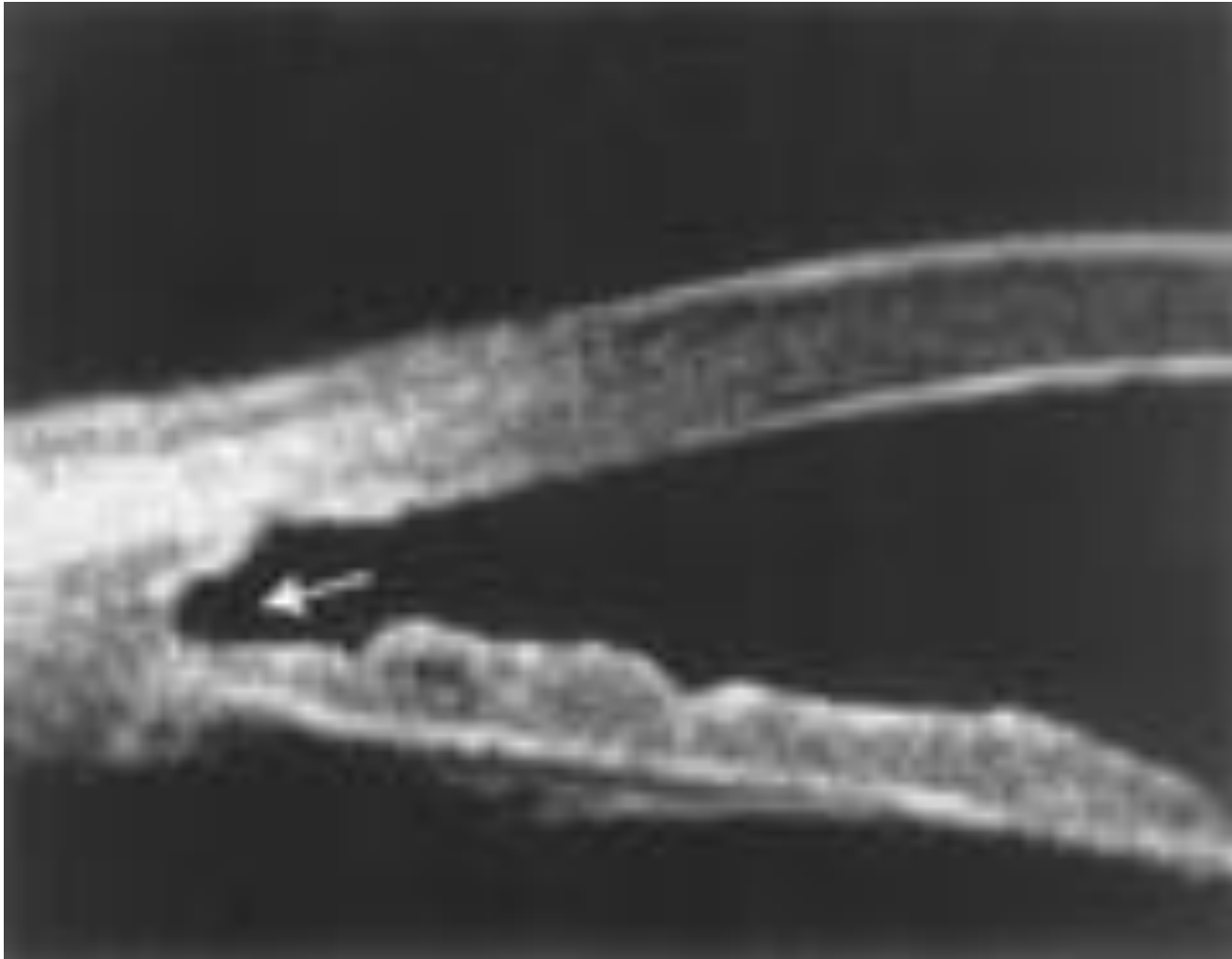Angle Recession Diagnosis

- The diagnosis of angle recession is made by patient history and clinical examination.
 - In cases of unilateral glaucoma or traumatic hyphema or after blunt trauma, angle recession should always be considered
- With milder injuries
 - the examiner may have to compare the gonioscopic appearance of two parts of the angle of 1 eye to identify subtle changes in the injured angle.

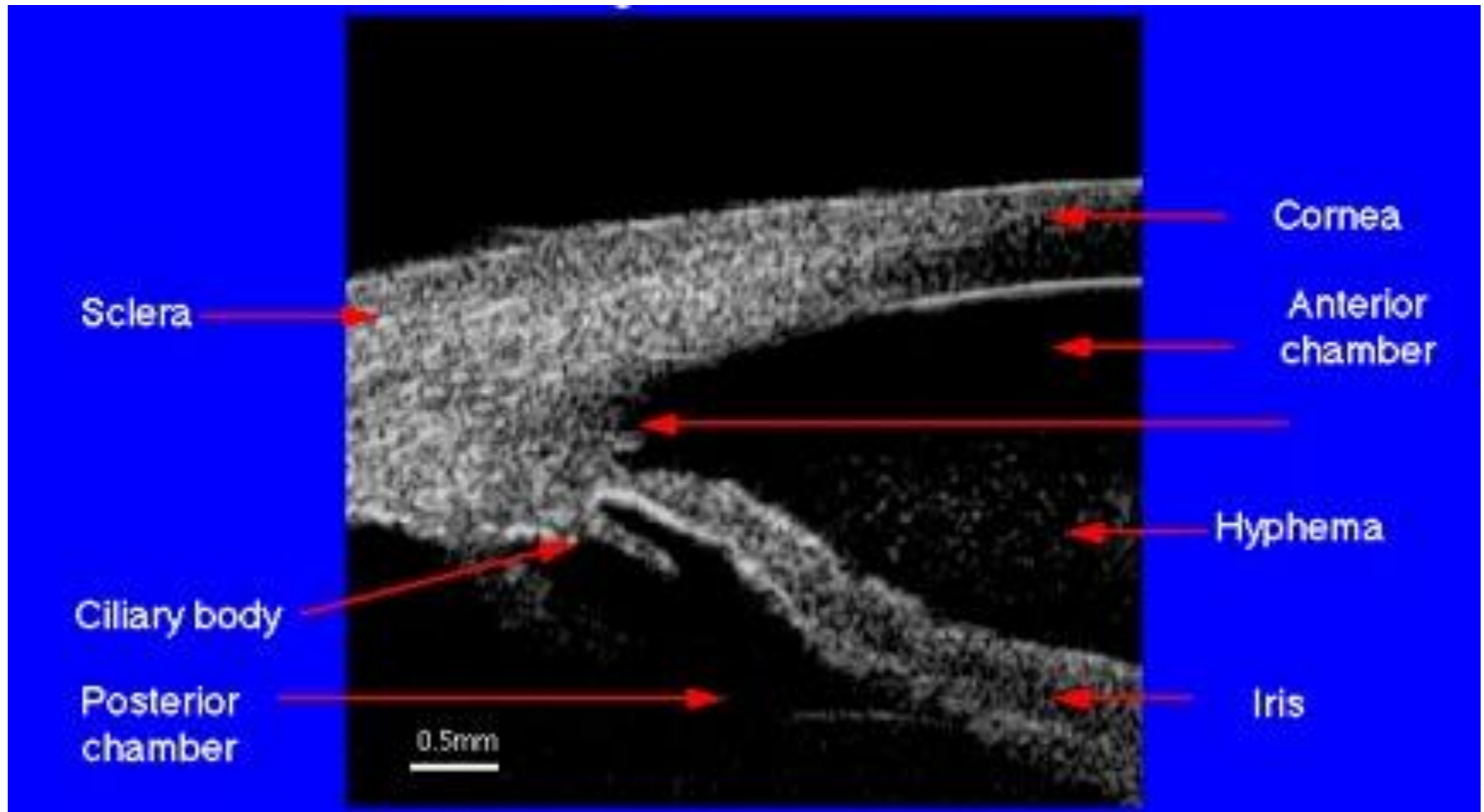
Angle Recession



Ultrasound Angle Recession



Anterior Segment OCT: Angle Recession



Treatment

- The IOP rise that occurs immediately after blunt trauma to the eye is usually self-limited and, in the majority of cases, can be controlled with medication alone.
- The late IOP rise that occurs years after the injury is more difficult to treat medically and may require surgical intervention.

Treatment

- Angle recession glaucoma is initially treated medically with the realization that miotics may be ineffective because of the disruption of the normal ciliary muscle–scleral spur relationship.
- There have been reports that miotics may cause a paradoxical increase in intraocular pressure in patients with angle recession, possibly by decreasing the uveoscleral outflow.

Treatment

- Glaucoma medications that decrease aqueous formation, such as beta blockers, carbonic anhydrase inhibitors, or alpha₂-agonists, may be useful.
- Prostaglandin analogs, which are claimed to increase uveoscleral outflow, may also be of benefit

Surgical Management

- Surgical management of eyes with angle recession glaucoma is more challenging than that in patients with open-angle glaucoma.
- Argon laser trabeculoplasty is usually unsatisfactory and fails to lower the IOP in this group of patients.
- Trabeculectomy has also been reported to have a lower success rate in eyes with angle recession glaucoma (43%) as compared to eyes in patients with open-angle glaucoma (74%).

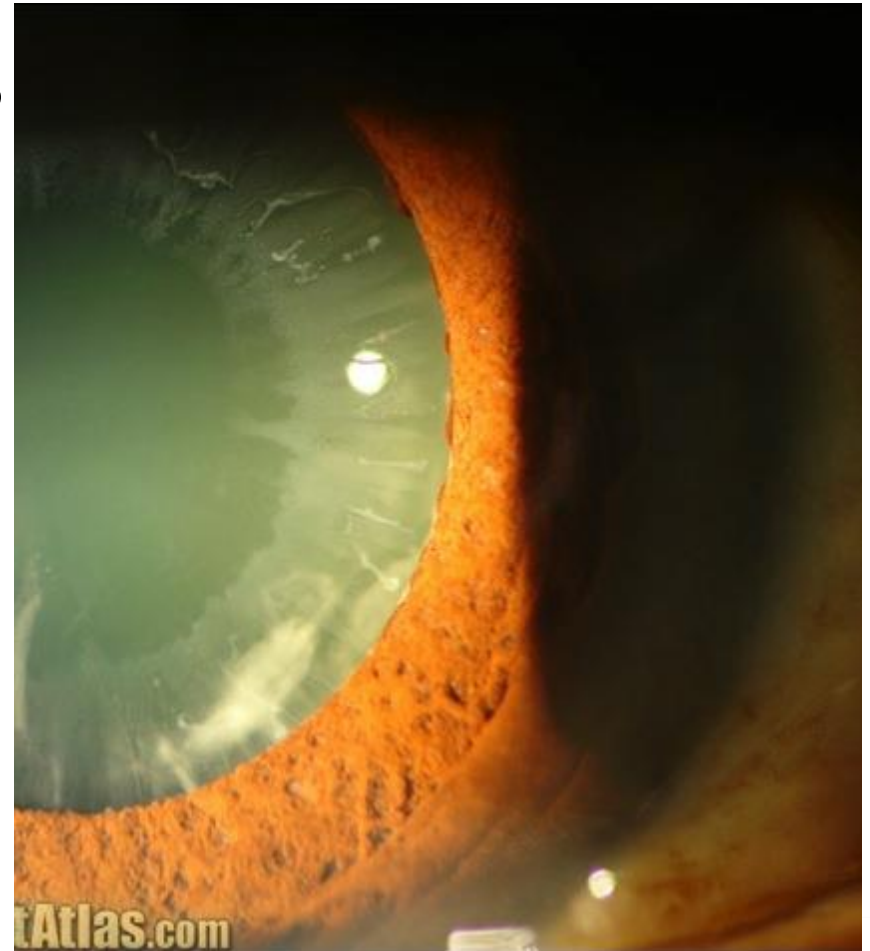
CASE

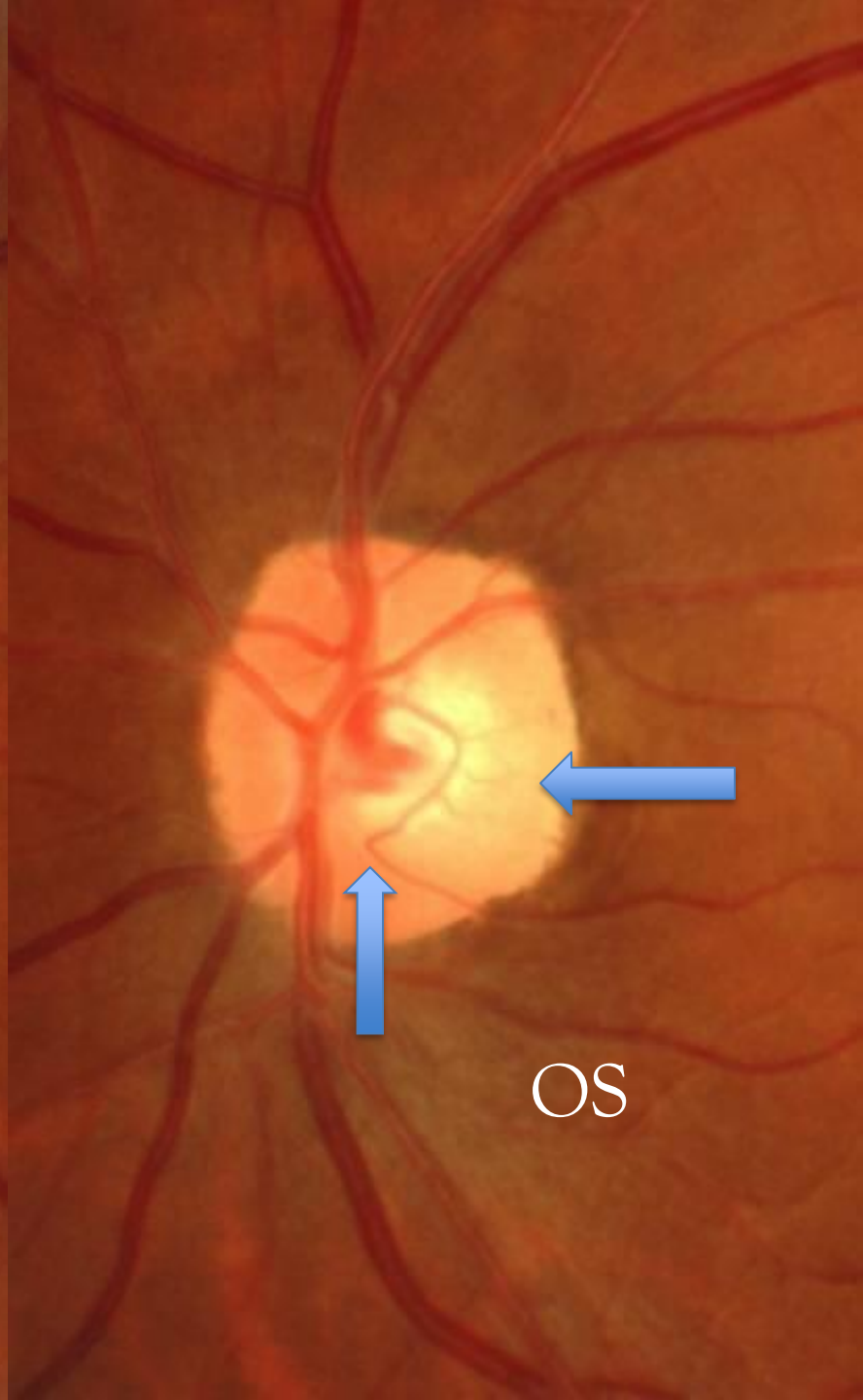
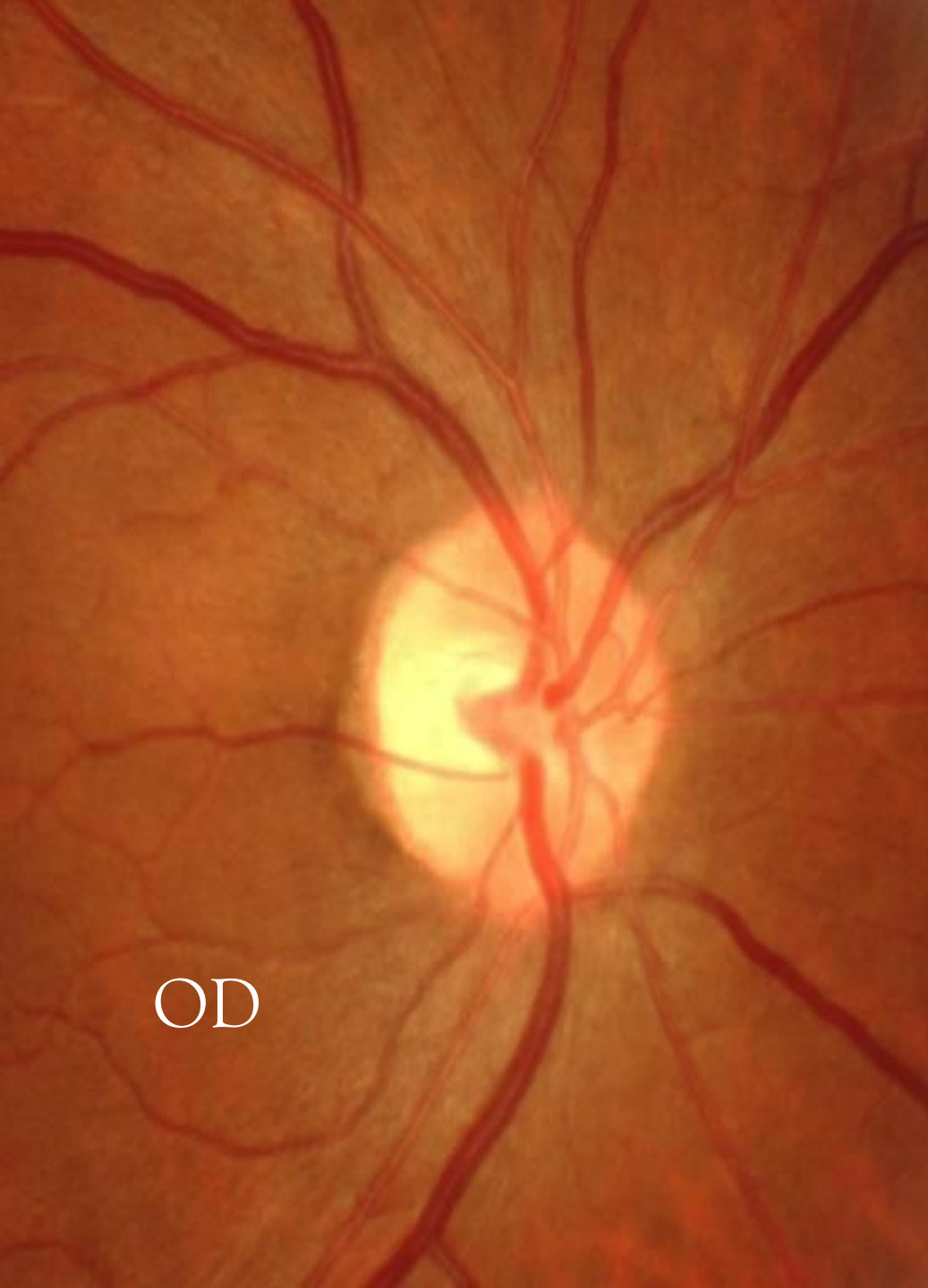Case

- 67 year old white male presents to the clinic noticing that his left eye is a bit blurry
 - PMHx: history of high cholesterol for which he is taking a statin
 - POHx: no history of eye surgeries or trauma
 - FOHx: aunt has glaucoma for which she takes drops

Case

- VA: 20/20 OD, 20/30 OS
- PERRL no APD
- Pachy: 540, 550 OD, OS
- IOP: 16, 40
- Fundus eval: see photos
- OD: c/d 0.45/0.45
- OS: c/d 06/0.5
- HVF: see photos





SINGLE FIELD ANALYSIS

EYE: LEFT

NAME: ██████████

ID: ██████████

DOB: 04-06-1947

CENTRAL 24-2 THRESHOLD TEST

FIXATION MONITOR: GAZE-BLINDSPOT

STIMULUS: III, WHITE

PUPIL DIAMETER: 6.4 MM

DATE: 06-17-2007

FIXATION TARGET: CENTRAL

BACKGROUND: 31.5 ASB

VISUAL ACUITY:

TIME: 2:04 PM

FIXATION LOSSES: 0/11

STRATEGY: SITA-FAST

RX: +4.00 DS DC X

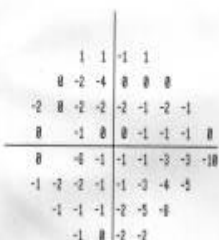

AGE: 60

FALSE POS ERRORS: 2 %

FALSE NEG ERRORS: 2 %

TEST DURATION: 02:51

FOVER: 31 DB 42



GHT
BORDERLINE

MD -2.42 DB P (5%)
PSD 1.90 DB P (5%)

TOTAL
DEVIATION

PATTERN
DEVIATION

○ (5%)
◐ (2%)
◑ (1%)
■ (0.5%)

PACIFIC UNIVERSITY FAMILY EYE CENTER
511 SW 10TH AVE
PORTLAND, OR

SINGLE FIELD ANALYSIS

EYE: RIGHT

NAME: ██████████

ID: ██████████

DOB: 04-06-1947

CENTRAL 24-2 THRESHOLD TEST

FIXATION MONITOR: GAZE-BLINDSPOT

STIMULUS: III, WHITE

PUPIL DIAMETER: 6.4 MM

DATE: 06-17-2007

FIXATION TARGET: CENTRAL

BACKGROUND: 31.5 ASB

VISUAL ACUITY:

TIME: 1:57 PM

FIXATION LOSSES: 3/13 XX

STRATEGY: SITA-FAST

RX: +3.50 DS DC X

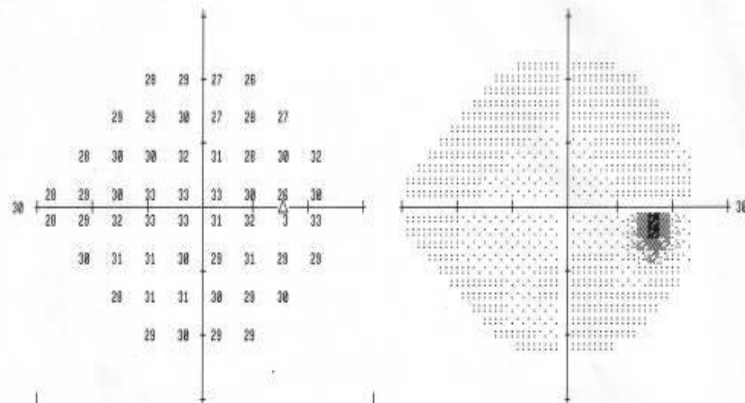
AGE: 60

FALSE POS ERRORS: 3 %

FALSE NEG ERRORS: 0 %

TEST DURATION: 02:55

FOVER: 6 DB ■



*** LOW TEST RELIABILITY ***

GHT
WITHIN NORMAL LIMITS

MD -6.30 DB
PSD 1.18 DB

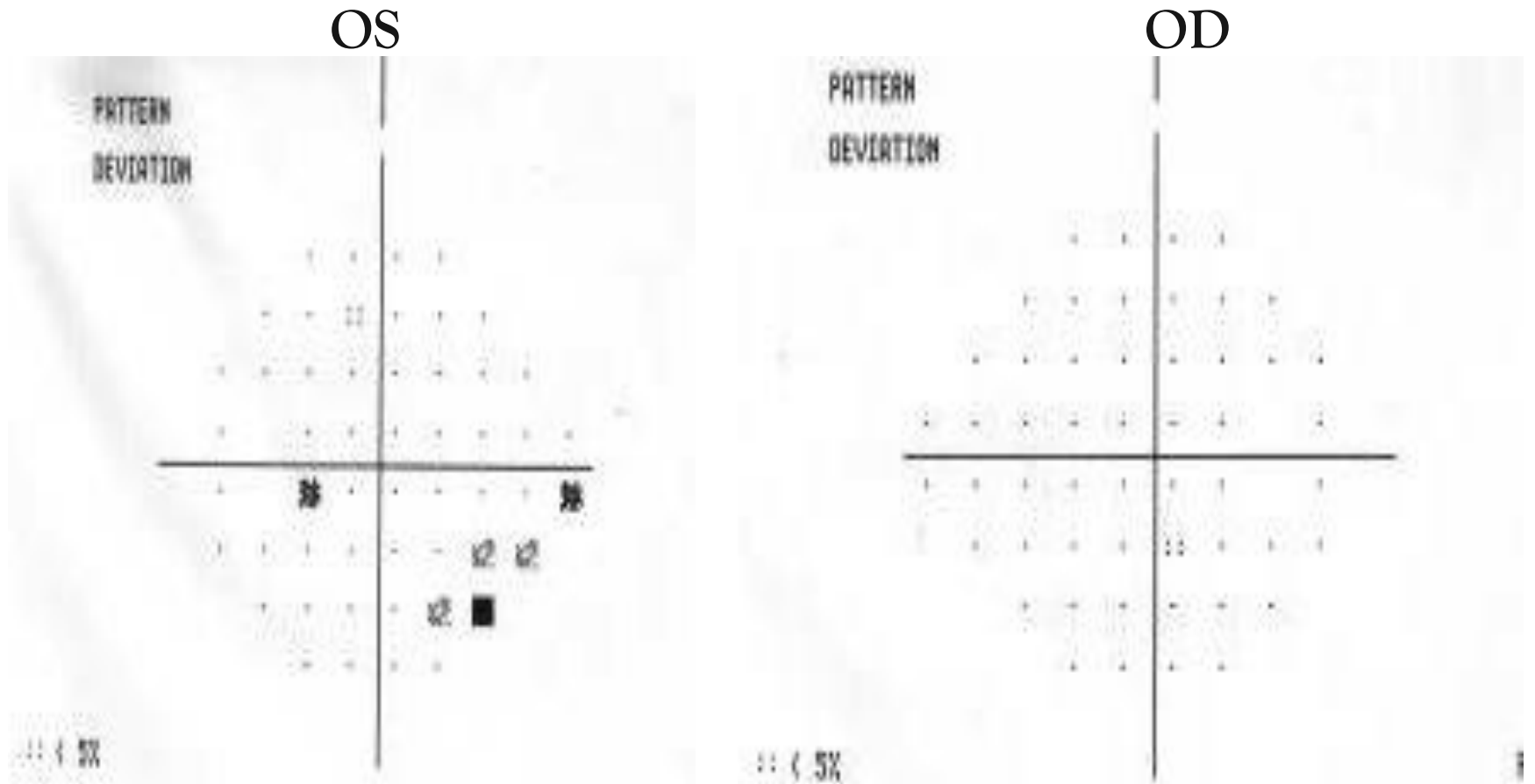
TOTAL
DEVIATION

PATTERN
DEVIATION

○ (5%)
◐ (2%)
◑ (1%)
■ (0.5%)

PACIFIC UNIVERSITY FAMILY EYE CENTER
511 SW 10TH AVE
PORTLAND, OR

Consider the below PSD plots.



Predict what TSNIT graphs you would obtain for this patient.

OS


SINGLE FIELD ANALYSIS

NAME: [REDACTED] ID: [REDACTED] EYE: LEFT DOB: 04-06-1947

CENTRAL 24-2 THRESHOLD TEST

FIXATION MONITOR: GAZE/BLINDSPOT
 FIXATION TARGET: CENTRAL
 FIXATION LOSSES: 0/11
 FALSE POS ERRORS: 2 %
 FALSE NEG ERRORS: 2 %
 TEST DURATION: 02:51
 FOVER: 31 DB 42

STIMULUS: III, WHITE
 BACKGROUND: 31.5 ASB
 STRATEGY: SITA-FAST
 PUPIL DIAMETER: 6.4 MM
 VISUAL ACUITY:
 RX: 44.00 DS DC X
 AGE: 68
 DATE: 06-17-2007
 TIME: 2:04 PM



0	0	-2	1
-1	-3	-5	-1
-3	0	-3	-2
-1	-2	-1	-1
-1	-7	-2	-4
-2	-2	-3	-2
-2	-1	-2	-5
-2	-1	-3	-2

TOTAL DEVIATION

PATTERN DEVIATION

GHT BORDERLINE

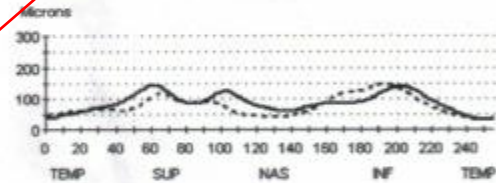
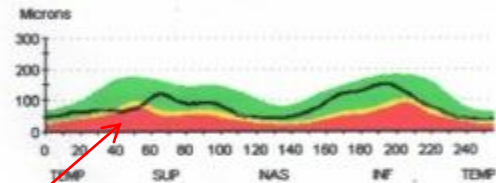
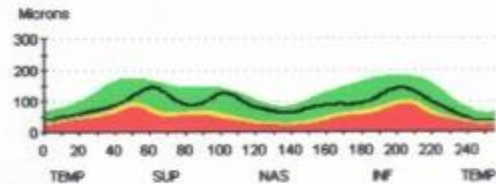
MD -2.42 DS P / S
 PSD 1.90 DS P / S

PACIFIC UNIVERSITY FAMILY EYE CENTER
 511 SW 10TH AVE
 PORTLAND, OR

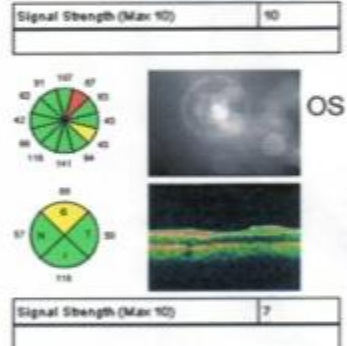
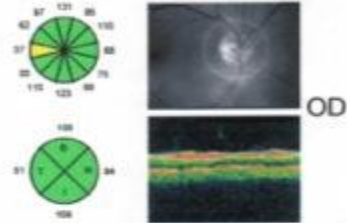
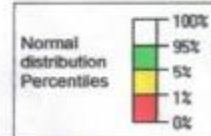
STRATUS OCT
 RNFL Thickness Average Analysis Report - 4.0.7 (0132)

DOB: 4/6/1947, ID: NA, Male

Scan Type: Fast RNFL Thickness (3.4)
 Scan Date: 9/17/2007
 Scan Length: 10.87 mm



OD	Scans used	1, 2, 3
OS	Scans used	1, 2, 3



	OD (N=3)	OS (N=3)	OD-OS
Imax/Smx	0.96	1.25	-0.27
Smax/Imx	1.02	0.80	0.22
Smax/Tavg	2.81	2.34	0.47
Imax/Tavg	2.74	2.93	-0.19
Smax/Navg	1.71	2.08	-0.37
Max-Min	112.00	114.00	-2.00
Smax	144.00	118.00	26.00
Imax	141.00	148.00	-7.00
Savg	108.00	98.00	20.00
Iavg	109.00	118.00	-9.00
Avg.Thick	98.09	78.22	9.87

Signature: _____

What We Did.

- We discussed with the patient:
 - appears he has early glaucomatous changes
 - early nasal step OS,
 - reduced NFL OS
 - Elevated IOP

Follow up

- Patient returned 14 days later for a follow up and his IOP had decreased from 40 to 22 in the left eye on the Travatan Z.
- Is this good enough????

Pseudoexfoliation Syndrome/Glaucoma (PXS/PXG)

PXS/PXG

- Characterized by the production and progressive accumulation of a fibrillar extracellular material in many ocular tissues
- PXS is reported to be the most common identifiable cause of open-angle glaucoma
 - However, not all participants with PXS develop glaucoma

Systemic Manifestations

- Pseudoexfoliation material (PXM) deposits around blood vessels of connective tissue.
- It has been identified as a generalized disorder of the extracellular matrix, involving the:
 - skin, extraocular muscles, heart, lung, liver, kidney, and meninges in addition to the eye
 - PXF was found to be associated with increased risk for cardiovascular or cerebrovascular morbidity in some studies
 - patients with Alzheimer's disease have a higher incidence of PXS

Increases with Age

- In Finland, the incidence rose from 10% for persons aged 60 to 69 years old to 33% in persons 80 to 89 years old.
- Increased incidence with age was also found in populations in Norway, Japan, Australian aborigines, and in the United States.
- Eyes with exfoliation may convert to PXG at a rate of approximately 30% per decade

PXF/PXG

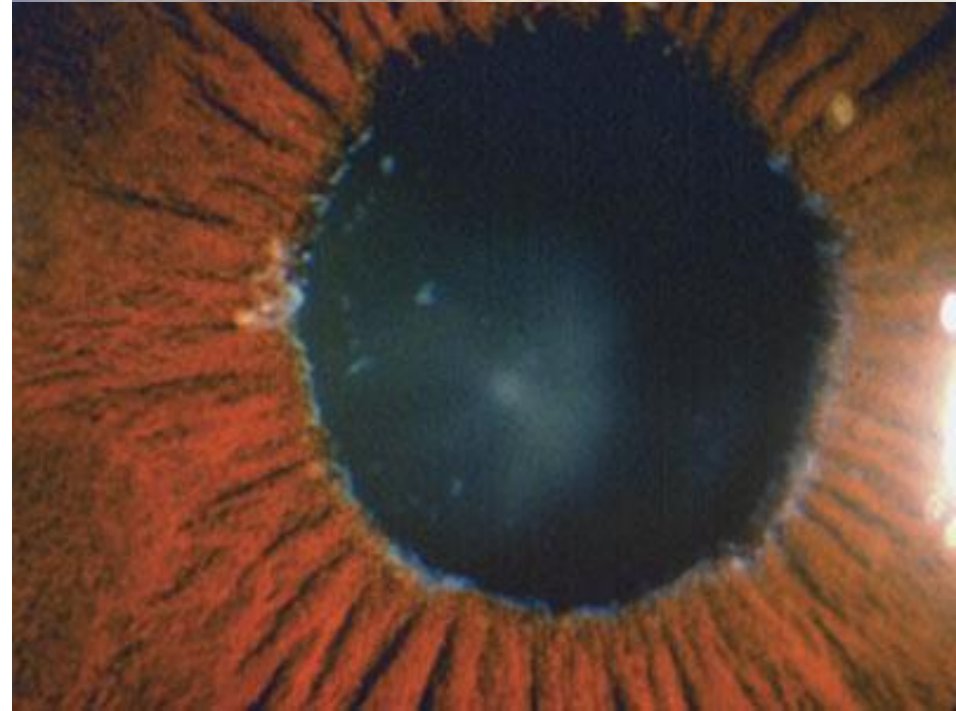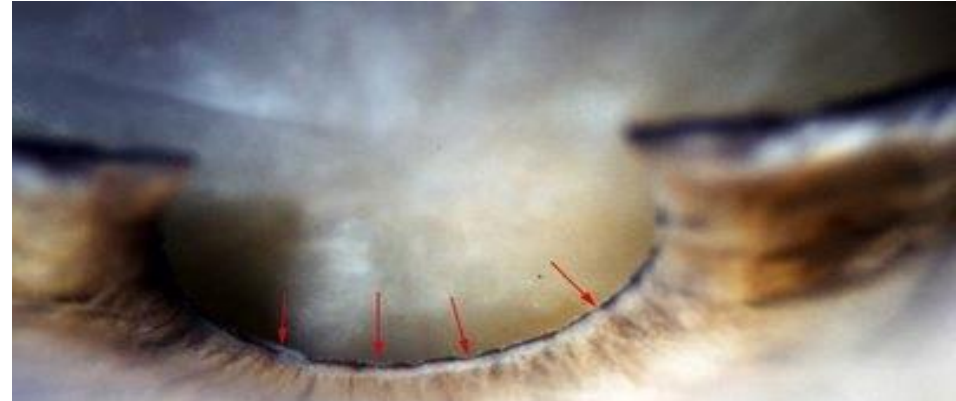
- Pseudoexfoliation glaucoma (PXG) is a severe type of glaucoma with a higher risk of blindness.
 - PXG is associated with a higher maximum and mean intraocular pressure (IOP) at the time of diagnosis, and a higher 24-hour pressure curve than primary open angle glaucoma (POAG)
 - PXG patients were seen to have significantly greater mean visual field defects at presentation than POAG patients

PXF/PXG

- Pseudoexfoliation glaucoma (PXG) is a severe type of glaucoma with a higher risk of blindness.
 - the IOP is harder to control in PXG than POAG
 - PXG is more difficult to manage clinically, with a higher incidence of treatment failure than POAG.

PXS Clinical Features

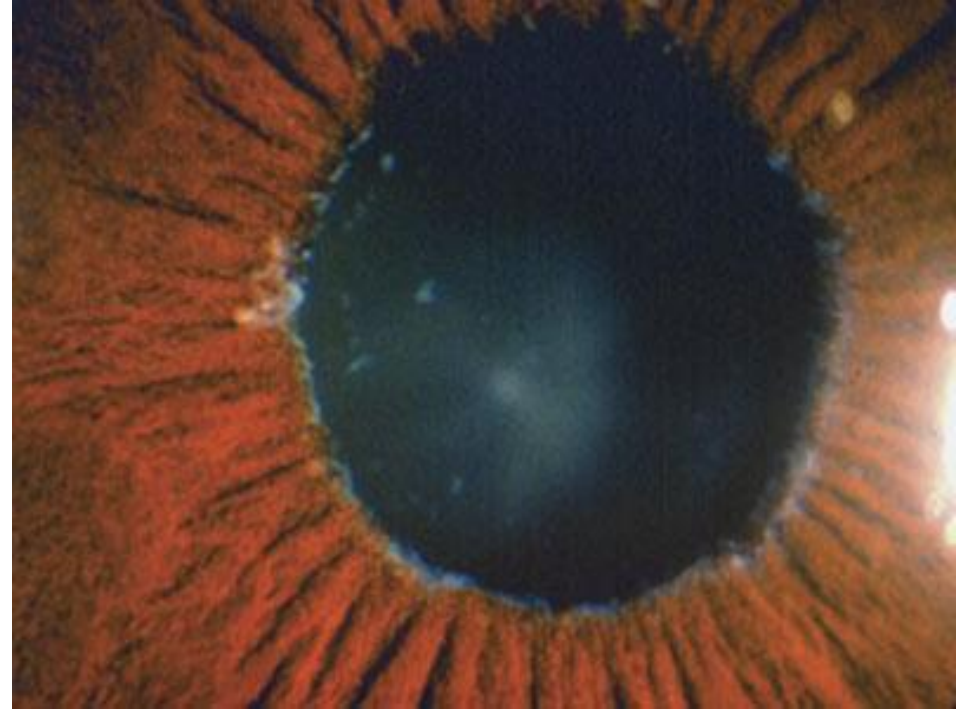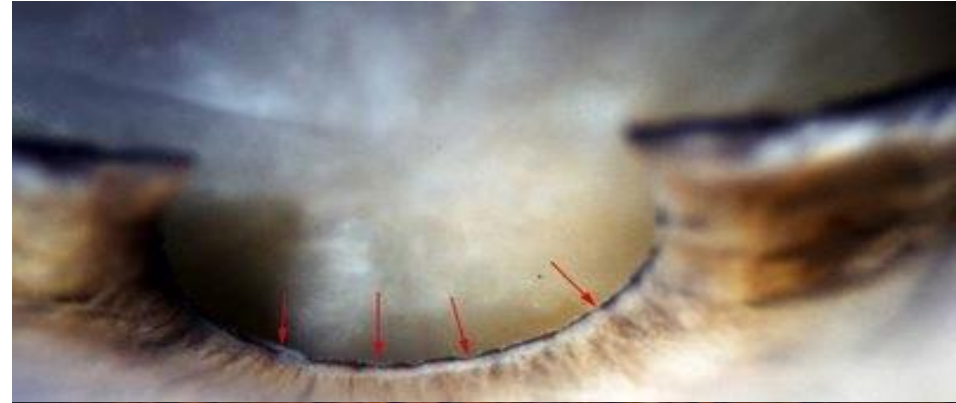
- PXS is defined by the presence of pseudoexfoliative material either at the pupil margin or on the lens capsule.



PXS Clinical Features

PXS typically presents unilaterally.

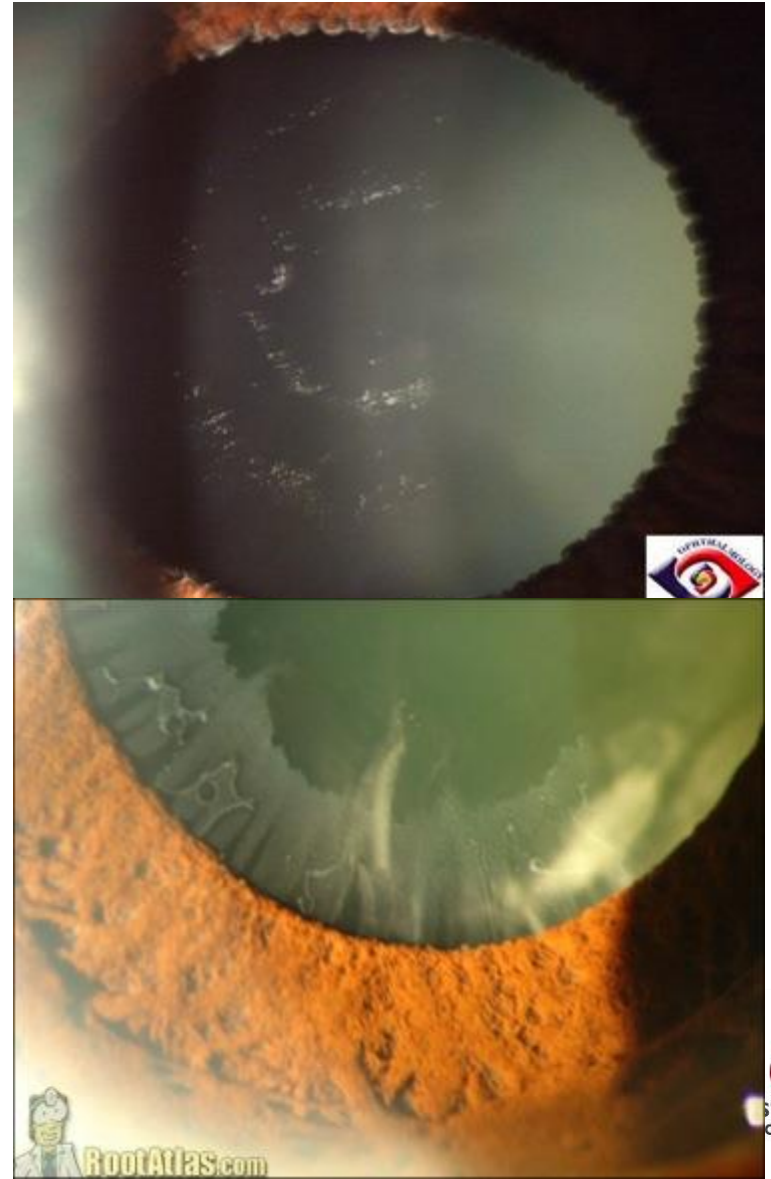
- Why this occurs remains unknown.
- The fellow eye develops signs of pseudoexfoliation in more than 40% of cases,



PXS Clinical Features

The most commonly recognized feature is the **3-ring sign** on the anterior lens capsule

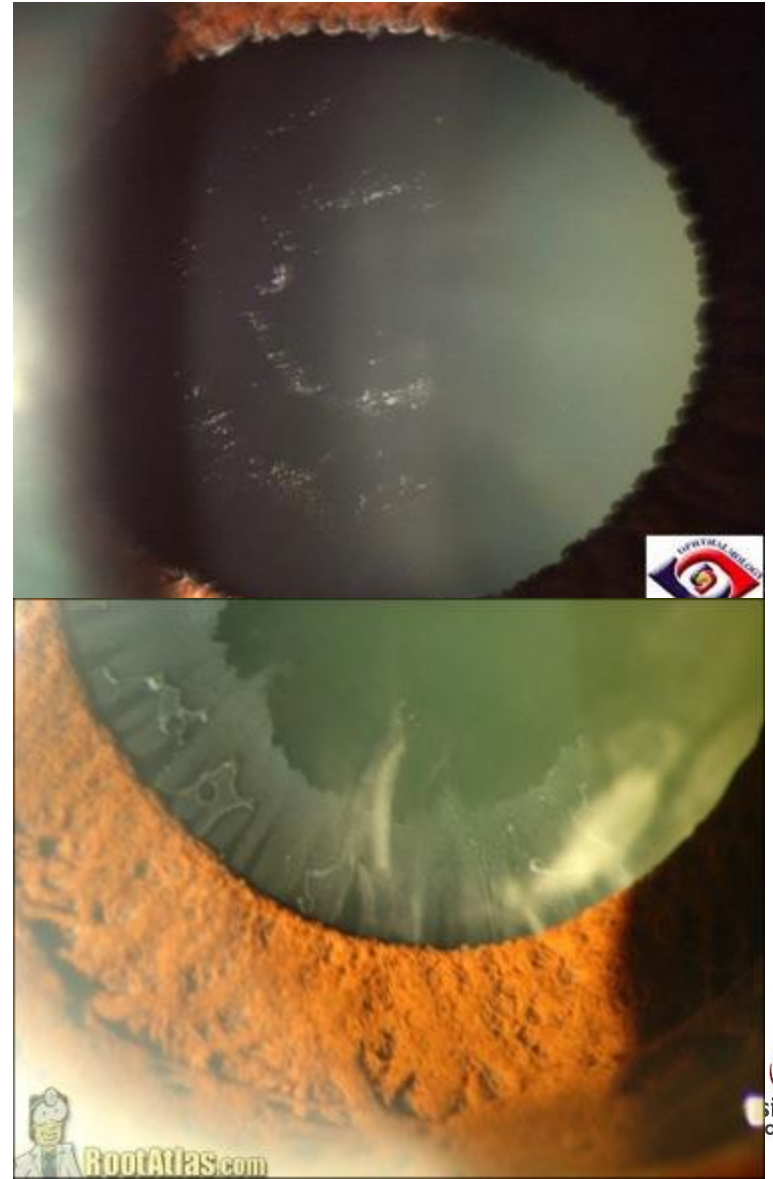
- formed by a central disk, a peripheral ring, and a clear zone, which separates the two.
- the clear zone varies in diameter and may exhibit curled edges.



PXS Clinical Features

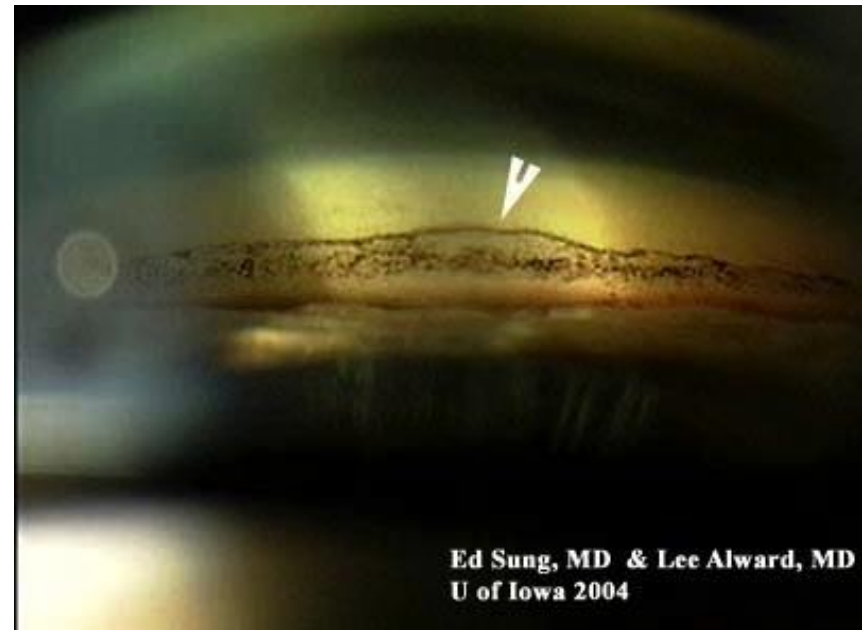
Peripupillary iris atrophy is a common and distinctive finding.

- it is best visualized using infrared transillumination



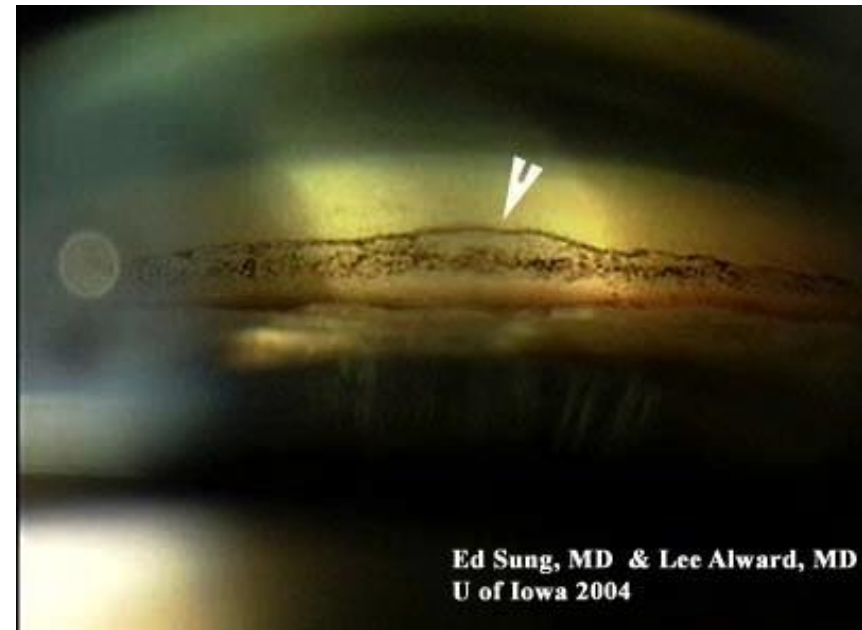
PXS Clinical Features

- Gonioscopy shows a discontinuous pigmentation of the trabecular meshwork
 - usually less dense than seen in pigmentary glaucoma.



PXS Clinical Features

- pigment characteristically is deposited on the Schwalbe line or anterior to the Schwalbe line (the Sampaolesi line).
- A high incidence of narrow, or occludable, angles in eyes with pseudoexfoliation has been reported.



PXS/PXG Treatment

- Current guidelines recommend a strategy of gradually increasing intervention in all forms of open-angle glaucoma
- Exfoliative glaucoma patients generally present with much higher more unstable IOP, the more aggressive approach of going directly to a fixed combination might be advisable in some cases

PXS/PXG Treatment

- Glaucoma in pseudoexfoliation is more resistant to medical therapy and has a poorer prognosis than primary open-angle glaucoma
- Combined therapy is required at the time of diagnosis in many patients with PXG who:
 - target pressures cannot be easily reached with monotherapy (those with high pressures, around 30 mmHg or higher)
 - have marked damage to the optic nerve head.
- Elevated IOP leads to glaucoma development in about 50% of patients

PXS/PXG Treatment

- The treatment of pseudoexfoliation glaucoma is the same as that of primary open-angle glaucoma;
 - though topical medications tend to be less effective than in POAG
 - miotics lower IOP,
 - but they aggravate the blood-aqueous barrier dysfunction and decrease iris mobility,
 - thereby increasing the risk of posterior synechiae and cataract formation.

PXS/PXG Treatment: Surgical

- Laser therapy has been shown in several studies to be as effective as medical therapy and makes no demands on patients in terms of compliance
- Published studies indicate that ALT is as effective and possibly more effective in the treatment of XFG than it is in POAG
 - However, efficacy tends to decline over time, reflecting the more progressive nature of the condition.

PXS/PXG Treatment: Surgical

In a study reviewing the records of patients where ALT was used as initial therapy, the proportion of POAG patients who did not require medication versus PXG patients

Time	% POAG	% PXG
After 2 years	77	80
After 5 years	67	54
After 8 years	67	36

PXS/PXG Treatment

- Argon laser trabeculoplasty is frequently used with excellent initial success.
 - Its hypotensive effect may be facilitated by enhanced heat absorption because of increased trabecular pigmentation.
- Selective laser trabeculoplasty (SLT) has been shown to be equivalent to argon laser trabeculoplasty in terms of lowering IOP at 1 year.
 - theoretical advantage of SLT is that SLT is a repeatable procedure because it does not seem to produce thermal damage to the trabecular meshwork.

PXS/PXG Surgical Treatment

- If medical therapy and laser therapy are unsuccessful to control the glaucoma
 - trabeculectomy can be performed with similar success rates to that of primary open-angle glaucoma
 - patients with pseudoexfoliation glaucoma have higher IOP, they tend to undergo glaucoma filtering surgery more frequently than patients with primary open-angle glaucoma.

PXS/PXG Surgical Treatment

- Cataracts occur more commonly in patients with pseudoexfoliation syndrome
 - weakness of the zonular fibers, spontaneous lens subluxation, and phacodonesis also can be present
 - cataract surgery alone or combined cataract surgery and glaucoma filtering surgery in the presence of pseudoexfoliation is associated with a higher incidence of intraoperative complications, most notably zonular dialysis, vitreous loss, and lens dislocation.

PXS and Alzheimer's?

- AD is a progressive neurodegenerative disorder characterized by neuronal and synaptic loss in the cerebral cortex leading to cognitive impairment, behavioral deficits and dementia.
- Cognitive areas, particularly the hippocampus, are most severely affected.
- Late-onset sporadic AD is most prevalent, affecting as many as half of the U.S. population over 85 years, whereas early-onset familial forms of the disease account only for about 5% of the total cases.

PXS and Alzheimer's?

- Although largely overlooked, visual impairment is also a common finding in AD patients, with a number of reports suggesting that it may result from undiagnosed glaucoma.
- The loss of specific neuronal populations is perhaps the most fundamental process shared by glaucoma and AD.
 - Visual dysfunction in glaucoma primarily results from the death of RGCs with axonal degeneration extending to the brain.

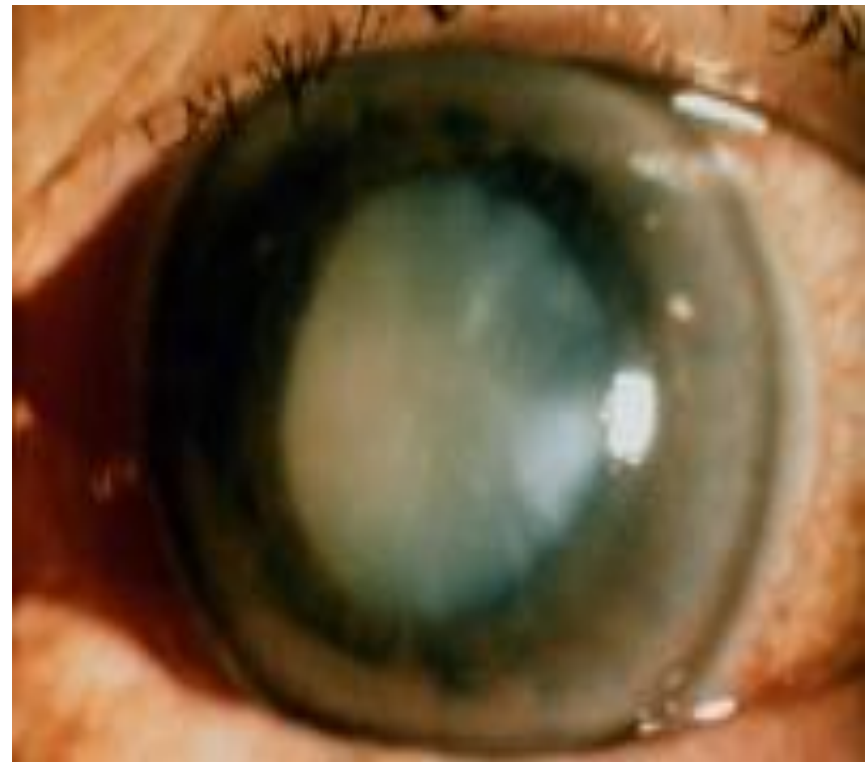
PXS and Alzheimer's?

- In a study by Cumurcu (2013) it was demonstrated that Alzheimer's type dementia was statistically significantly increased in the PXS group as compared to the age- and sex- matched control groups
 - an increased AD prevalence in patients with PXS when compared with the control group.
- patients with Alzheimer's disease have a higher incidence of PXS, characterized by the accumulation of an abnormal amyloid-like material in the anterior segment of the eye.

Question

70 year old patient presents with an IOP of 45, ONH cupping and VF defects. With respect to the photo, what kind of glaucoma does this patient likely have?

1. Phacomorphic glaucoma
2. Phacolytic glaucoma
3. Lens-particle glaucoma
4. Phacoanaphylactic glaucoma



LEN INDUCED GLAUCOMA

Clinical Pearl

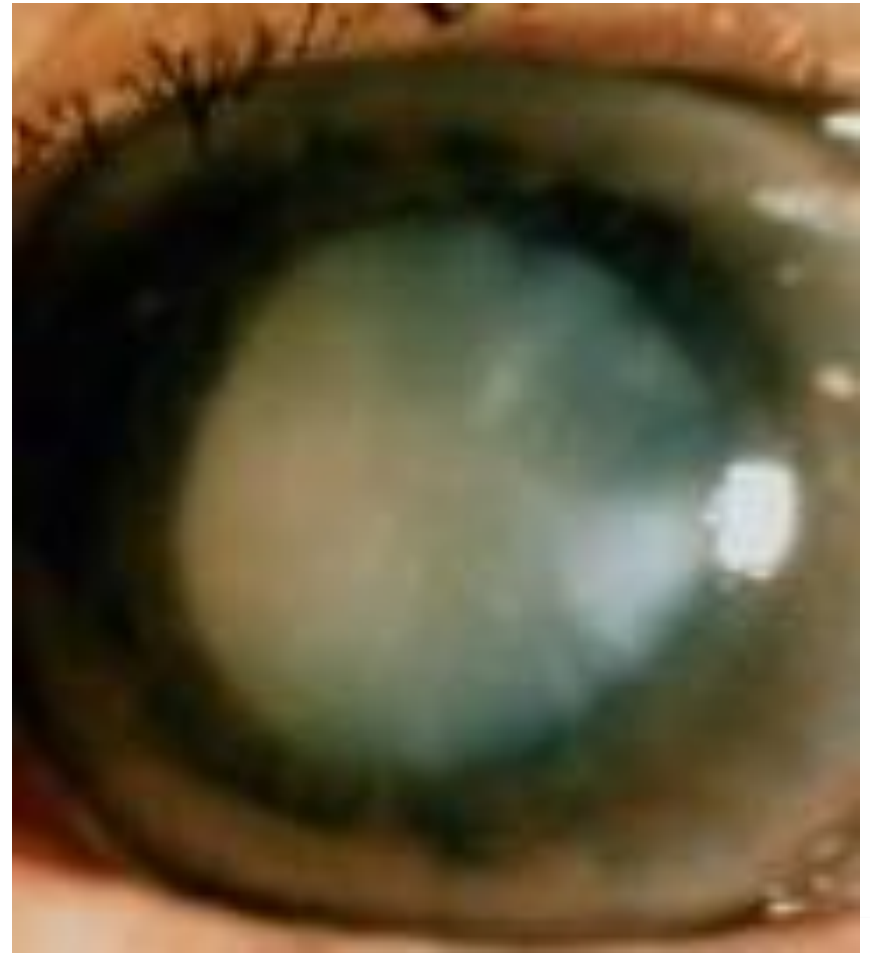- In all of these cases:
 - the glaucoma is typically very symptomatic with pain and redness in the involved eye, and cells and flare in the anterior chamber.
 - frequently, an advanced cataract in the involved eye severely reduces vision.

Phacomorphic

- A senile cataractous lens that has progressed enough to become intumescent
 - has an increased anteroposterior length,
 - which could lead to pupillary block.
 - this type of glaucoma is named phacomorphic

Phacomorphic Glaucoma

- often occurs from a mature cataract
- could present asymptotically as chronic angle-closure glaucoma,
 - however it more often presents as acute angle closure glaucoma.



Treatment

- Treatment focuses on two objectives:
 - lower the IOP as soon as possible and
 - prevent the diseased and fellow eye from another episode.
- Initially, IOP-lowering medications are used.
 - Topical beta blockers,
 - carbonic anhydrase inhibitors, and
 - hyperosmotic agents (mannitol IV) are the mainstay of medical treatment.

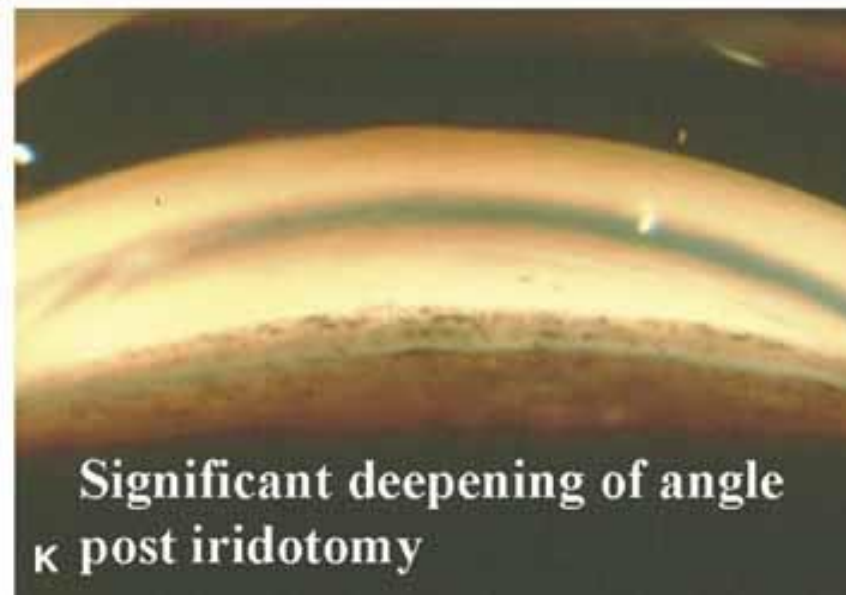
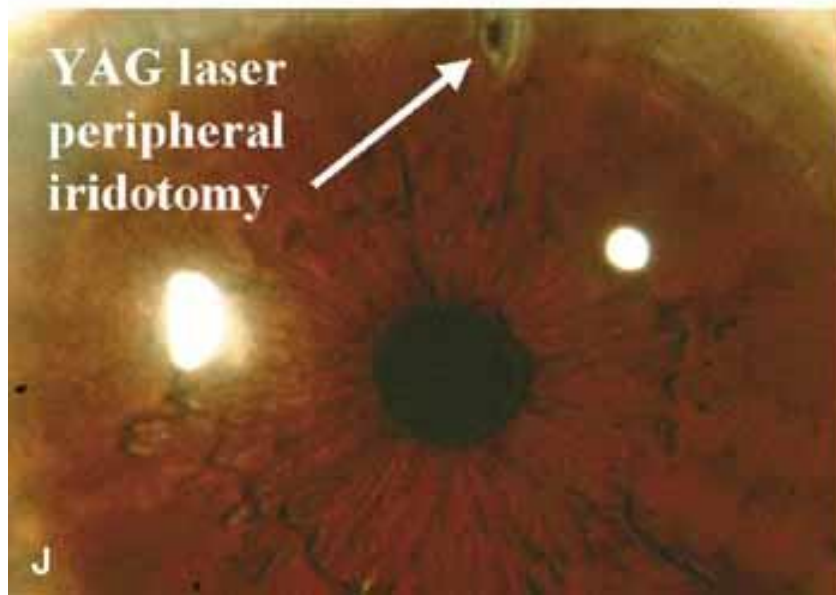
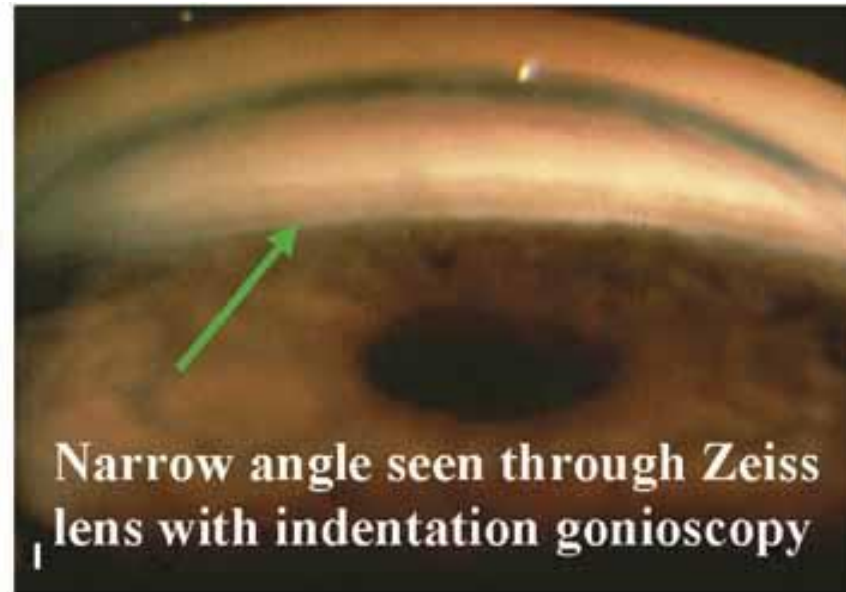
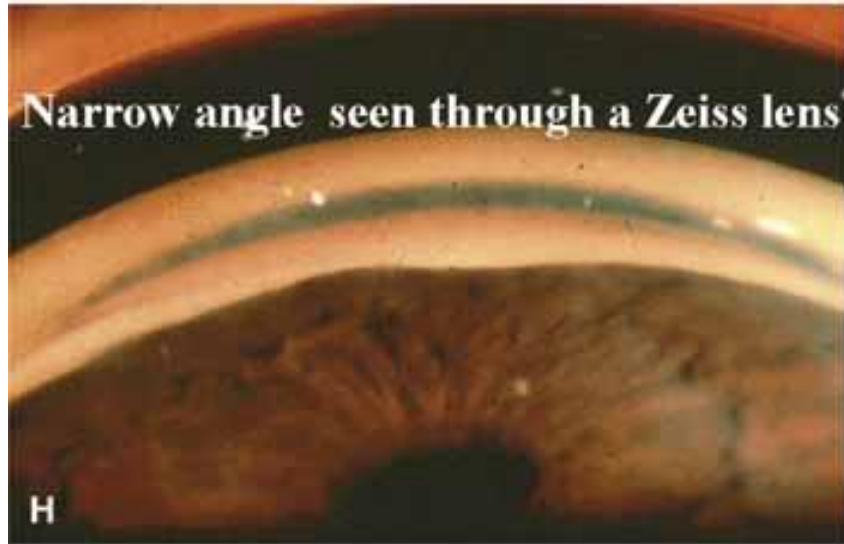
Treatment

- Parasympathomimetic agents (pilocarpine 1% or 2%) tend to increase pupillary block, so they should be used with caution.
- In the case of phacomorphic glaucoma:
 - after IOP control and establishing intraocular inflammation
 - proceed to cataract extraction
 - which erases the major causative factor of angle-closure glaucoma

Surgical Treatment

- As soon as IOP controlled and sufficient corneal clarity is established
 - Laser peripheral iridotomy (LPI) is the established first-line treatment for angle closure
 - relieves the pupil block component present

Angle Closure Treatment: LPI

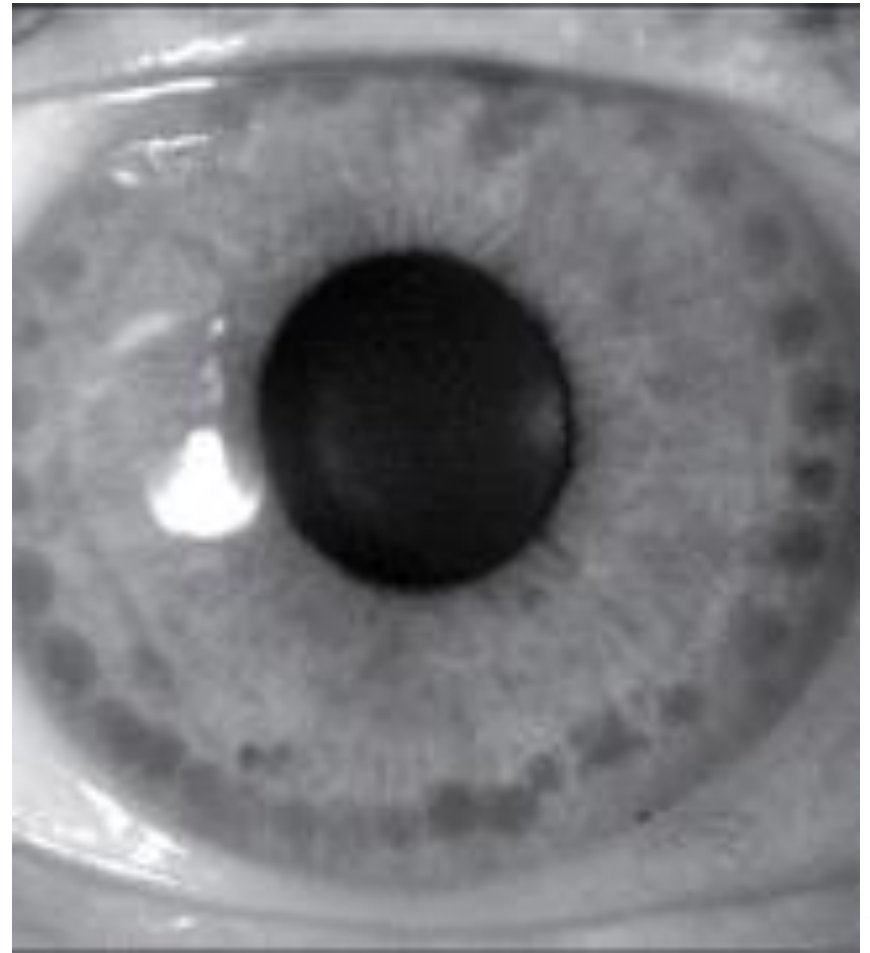


Surgical Treatment: ALPI

- Recent trials have demonstrated that argon laser peripheral iridoplasty (ALPI) is superior to conventional treatments in controlling IOP in primary angle closure glaucoma
- ALPI has traditionally been used to treat patients resistant to conventional treatment

Surgical Treatment: ALPI

- Procedure involves placement of a ring of contraction burns on the peripheral iris
 - results in contraction of the iris stroma near the angle mechanically opening the angle and lowering IOP



Surgical Treatment: Cataract Surgery

- Ultimately, patients require cataract surgery to remove the secondary angle closure
 - There is an increased risk of complications during the surgery due to the advanced stage of cataract development

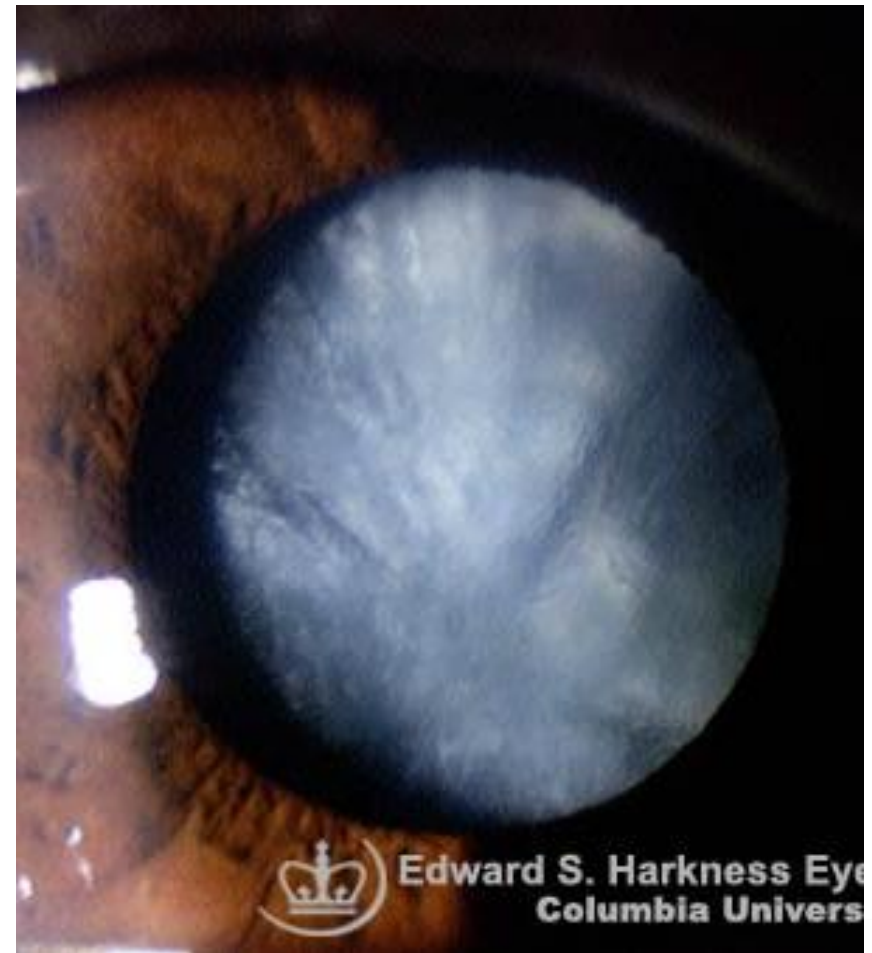Phacomorphic Glaucoma

Clinical Pearl:

In patients with hypermature cataracts and shallow anterior chambers with angle closure, consider phacomorphic glaucoma, especially if the fellow lens has less intumescence and there is a deeper chamber.

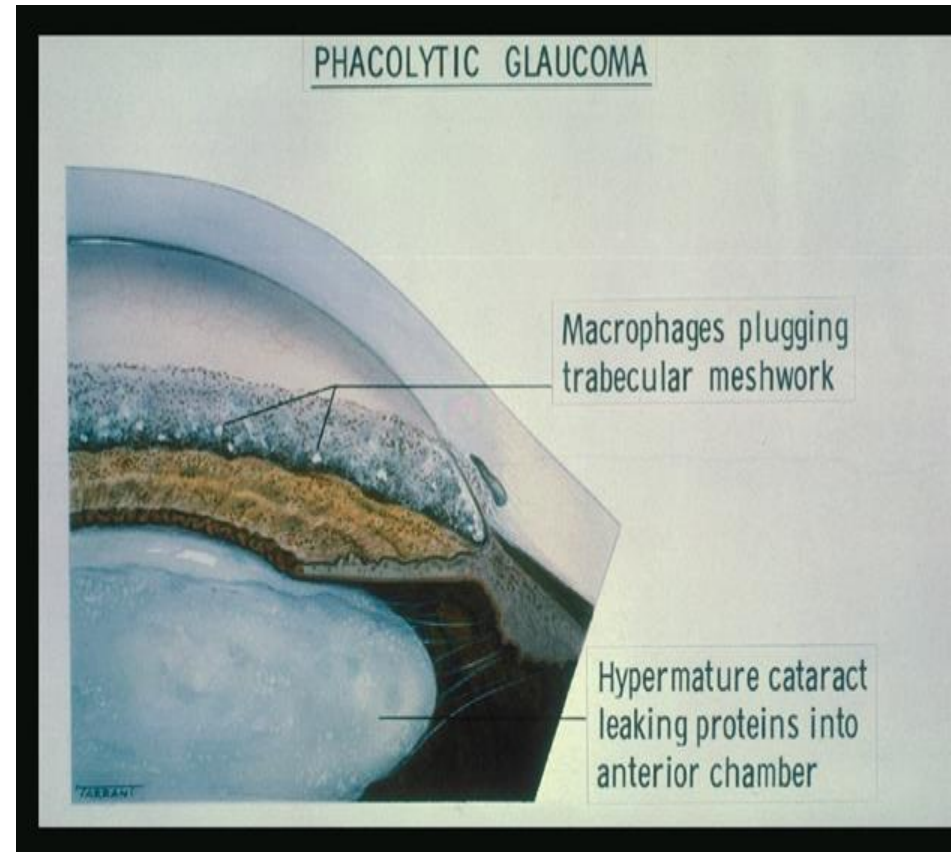
Phacolytic Glaucoma

- This acute open-angle glaucoma is the result of:
 - leakage of lenticular material from senile hypermature or Morgagnian cataract through an intact lens capsule



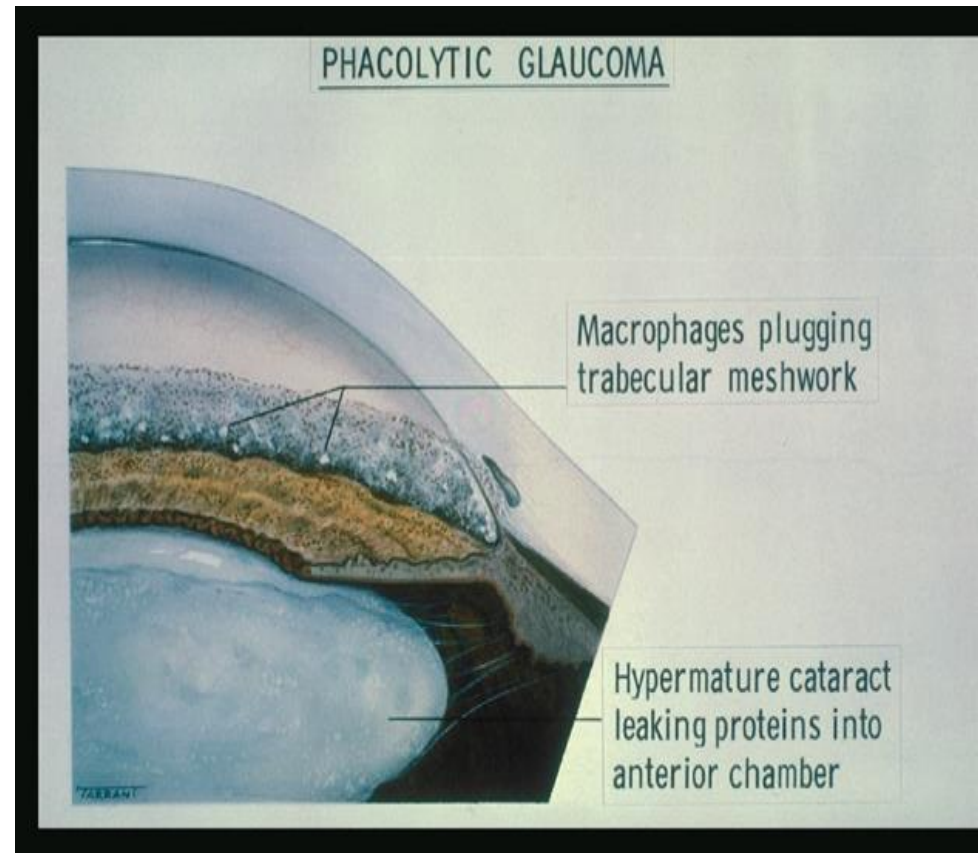
Phacolytic Glaucoma

- The presentation is:
 - red and painful eye,
 - history of gradual decline of visual acuity reflecting the slow maturation of the cataract,
 - Vision is typically 20/400 or worse (LP)
 - corneal edema,
 - high IOP (>35 mm Hg),
 - open-angle in gonioscopy,



Phacolytic Glaucoma

- heavy flare, and aqueous cells larger than the lymphocytes seen in uveitis
 - these cells are thought to be macrophages swollen with eosinophilic lenticular material which they have engulfed.



Phacolytic Glaucoma

- Soft white patches on the lens capsule can be observed
 - aggregates of macrophages trying to seal the site of leakage
 - the fellow eye usually has a mature cataract and a deep anterior chamber.

Phacolytic Glaucoma Treatment

- The majority of patients with phacolytic glaucoma can be managed through:
 - topical cycloplegia,
 - topical steroids, and
 - aqueous suppressants.
- If despite intensive antiglaucomatous therapy, IOP continues to increase,
 - emergency admission may be advocated, and in
 - rare instances urgent cataract or vitreoretinal surgery may be required.

Clinical Pearl

Phacomorphic and phacolytic glaucoma develop only in eyes with hypermature cataracts. Vision typically ranges from 20/400 to light perception. If vision is better than 20/400, consider another cause for the glaucoma.

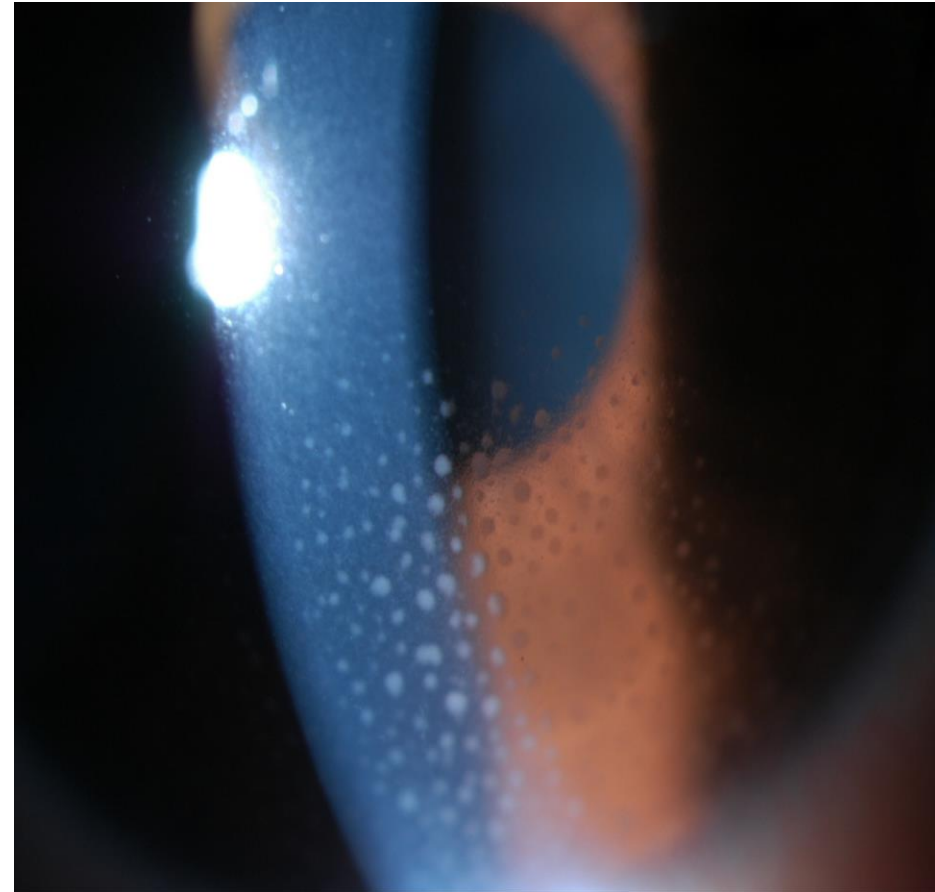
Inflammation Induced Glaucoma

Case

- 30 BF presents with eye pain in both eyes for the past several days
 - Severe pain (8/10)
 - Never had eye exam before
- PMHx:
 - Has chronic bronchitis
 - Rash on legs
 - Has recently lost weight and has a fever
 - Taking aspirin for pain

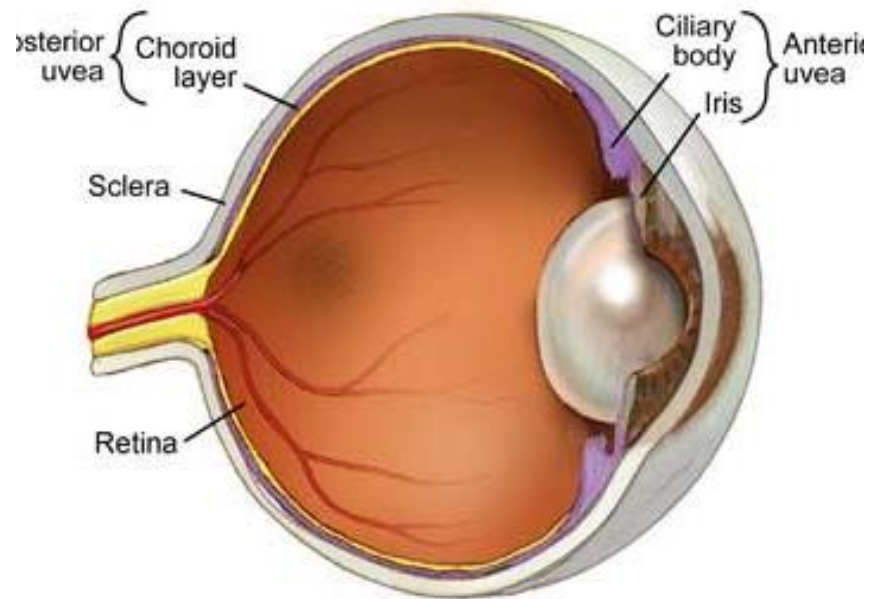
Ocular Health Assessment

- VA: 20/30 OD, OS
- PERRL
- FTFC
- EOM"s: FROM with eye pain in all quadrants
- SLE: 3+ injection, 3+ cells and trace flare, deposits on endo (see photo)
- IOP: 16, 16 mmHg
- DFE: sheathing of posterior pole vasculature, vitreal cells, and white fluffy deposits at ora.



Uveitis

- Uveitis frequently is nonspecific but can be associated with:
 - systemic disease,
 - occur following trauma, or
 - be the result of a primary ocular disorder such as:
 - Fuchs's heterochromic iridocyclitis or
 - glaucomatocyclitic crisis (ie, Posner-Schlossman syndrome)



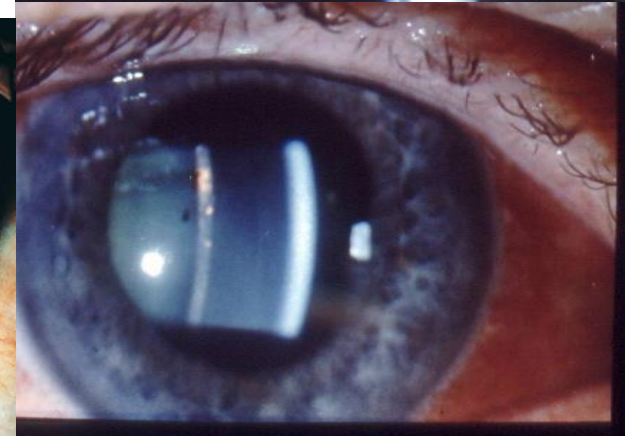
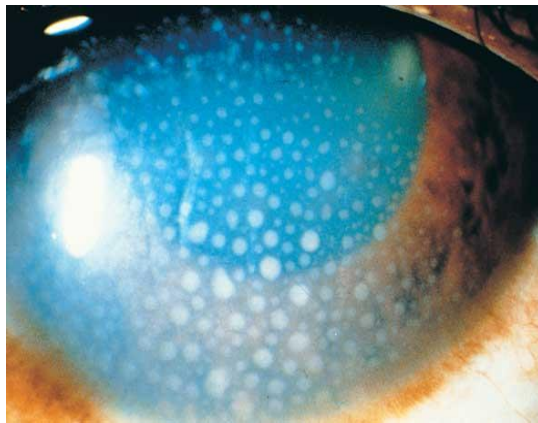
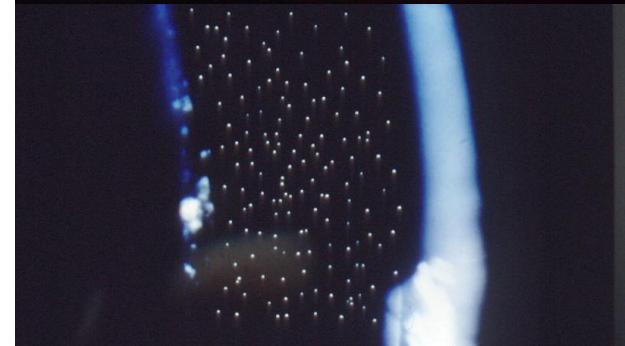
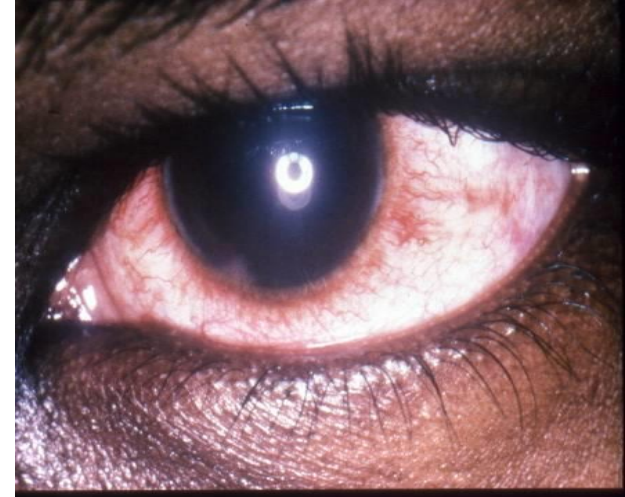Mayo Foundation for Medical Education and Research. All rights reserved.

Uveitis

- The clinical features of anterior uveitis are readily recognizable
- complaints of:
 - photophobia,
 - pain,
 - blurred or variable vision
- A change in the blood-aqueous barrier results in the liberation of protein and cellular matter into the anterior chamber and the vitreous.

Uveitis

- Clinical findings of:
 - circumlimbal hyperemia,
 - cells and flare in the aqueous and anterior vitreous, and
 - keratitic and trabecular precipitates



Uveitis

- IOP elevation in uveitis is the end result of a combination of changes in:
 - aqueous composition (increased protein and hence viscosity),
 - aqueous production (reduced),
 - conventional outflow (reduced), and
 - uveoscleral outflow (increased)

Uveitis

- a reduction in the IOP is often seen in the acute uveitis episode
 - paradoxically, an eye with uveitic glaucoma may develop chronic hypotony from ciliary insufficiency in the longer term.
- outflow facility is reduced in the presence of:
 - increased aqueous protein concentration,
 - inflammatory cytokines,
 - pigment deposition, and
 - direct inflammation also influence trabeculocyte function in uveitis.

Uveitis

- The clinician should be alert to the possibility of glaucoma secondary to the inflammation.
- Attention should be given to the possibility that primary acute angle-closure glaucoma may be present, since many of the clinical features are similar.

Uveitis: Treatment

- “Classical treatment”:
 - Pred forte: every 1-2 hours, ensure taper
 - Pred forte: prednisolone acetate formulation which allows penetration through cornea to anterior chamber
- Newer treatment option:
 - Durezol

Treatment Options

- Durezol:
 - Difluprednate
 - only difluorinated steroid
 - Steroid emulsion
 - BAK free
 - Increased “potency” so dosing needs to be less than “classical treatment” with Pred Forte
 - rough recommendation is 1/2 dosing of Pred Forte

Cycloplegia

- Cycloplegia/mydriatics:
 - Homatropine 5% qd-bid
- Provides three useful functions in the treatment of uveitis:
 - Prevents synechiae formation
 - Takes ciliary body out of spasm thus reducing pain
 - Reduces inflammation

Common Uveitic Causes

- Uveitis is seen in conditions such as:
 - sarcoidosis,
 - Reiters syndrome (reactive arthritis),
 - ankylosing spondylitis,
 - syphilis and
 - Juvenile idiopathic arthritis,
 - as well as a number of other systemic conditions.

Uveitic Glaucoma

- Any uveitic process is capable of producing secondary angle-closure or open-angle glaucoma.
 - Ocular inflammation that results in secondary anterior uveitis has the potential to produce an elevation in IOP and subsequently, if left unchecked, glaucoma.
 - Common causes include:
 - herpes simplex,
 - herpes zoster ophthalmicus, and
 - rubella

Uveitic Glaucoma

- Chronic inflammation can result in permanent changes to ocular structures, causing anomalies such as:
 - iris atrophy,
 - synechiae, and cataract.
- The established mode of treatment, topical and systemic corticosteroids, can also result in permanent ocular tissue changes.

Uveitic Glaucoma

- overall prevalence of 20% in a clinic-based study of 1099 uveitis sufferers
- Glaucoma is considerably more common than this in a number of specific uveitic syndromes, such as:
 - Fuchs heterochromic cyclitis (27%),
 - Sarcoidosis (34%),
 - herpes simplex keratouveitis (54%) , and
 - zoster uveitis (38%),
- However, the most common cause is idiopathic acute anterior uveitis, even though the reported prevalence is lower.

Uveitic Glaucoma

- Glaucoma secondary to juvenile idiopathic arthritis (JIA) is a potentially blinding complication in children and young adults.
 - 35% of affected eyes with secondary glaucoma lost all vision in one large previous study

Uveitic Glaucoma Management

- Despite initial fears, it seems that prostaglandin receptor agonists have a propensity to increase the activity of uveitis in only a very small percentage of patients
- However, prostaglandin agonists should still be used cautiously in uveitics with a history of cystoid macular edema or herpetic keratouveitis

Uveitic Glaucoma Management

- The first step in the management of glaucoma resulting from anterior uveitis is medical control of the inflammation and prevention of complications.
 - topical corticosteroids,
 - mydriatics/cycloplegics should be employed

Uveitic Glaucoma Management

- Homatropine 5% used twice daily in combination with a sympathomimetic such as phenylephrine 2.5% will reduce the discomfort caused by photophobia and ciliary spasm.
- Atropine has also been shown to lower IOP by increasing uveoscleral outflow.
- Cycloplegic agents will help to stabilize the permeability of the iris vasculature.
- Cycloplegics help to prevent synechiae from forming, and in combination with phenylephrine may help to break formed synechiae.

Uveitic Glaucoma Management

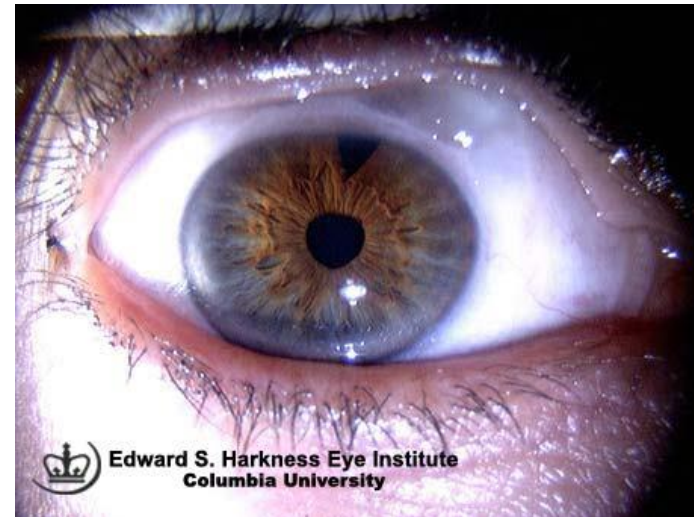
- Topical corticosteroids inhibit the inflammatory response and decrease capillary permeability
 - restoring the blood- aqueous homeostasis and reducing the release of cellular exudates and protein.
- Penetration of topical corticosteroids is increased by the inflammatory response
 - if topical agents prove to be ineffective, subconjunctival or systemic steroids may be administered.

Uveitic Glaucoma Management

- Elimination of the anterior uveitis initiates the treatment of the accompanying secondary glaucoma.
- Mydriatic cycloplegics will prevent pupillary block and peripheral anterior synechiae.
- If the IOP remains elevated
 - adrenergic antagonists, carbonic anhydrase inhibitors or B-blockers
- Miotics should be avoided since they may aggravate the inflammation and precipitate pupillary block and iris bombe.

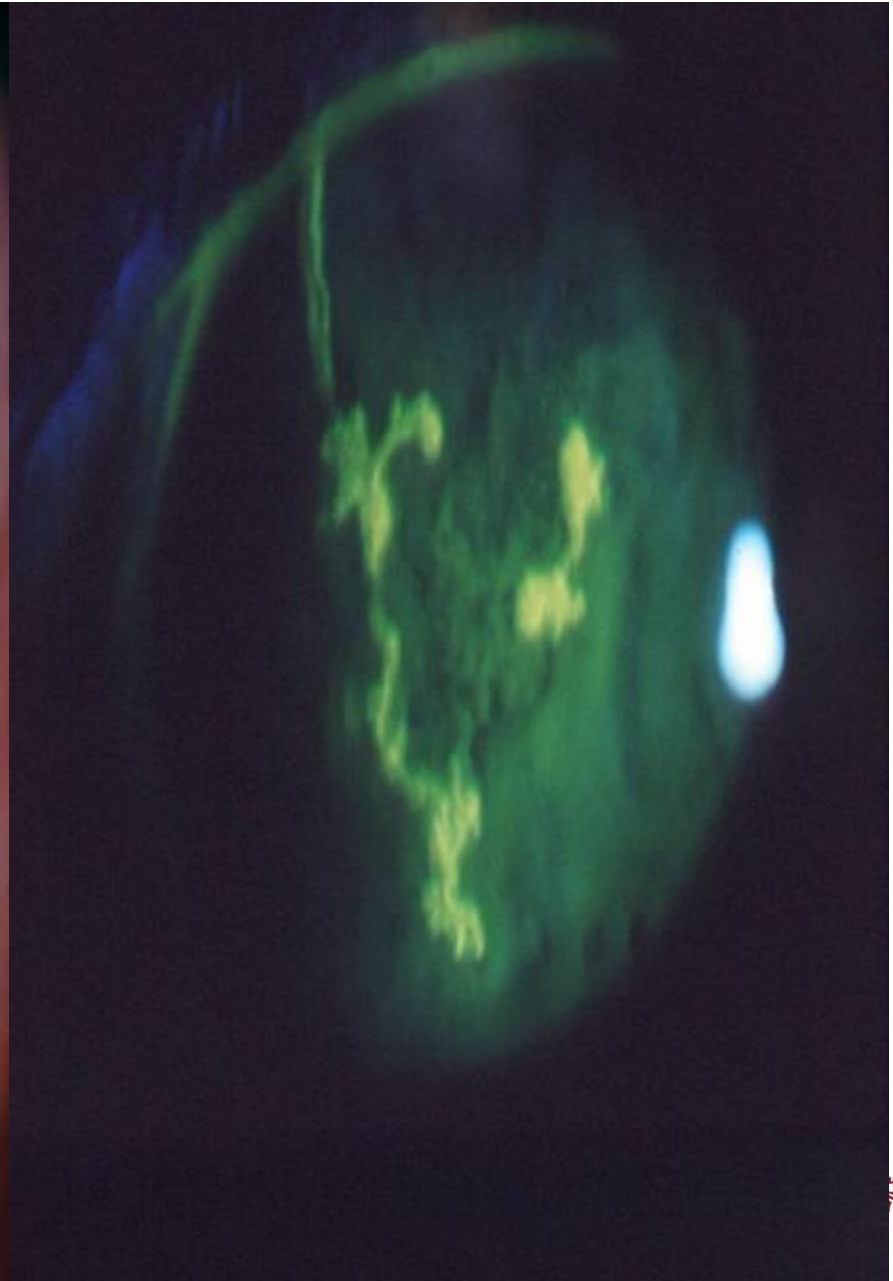
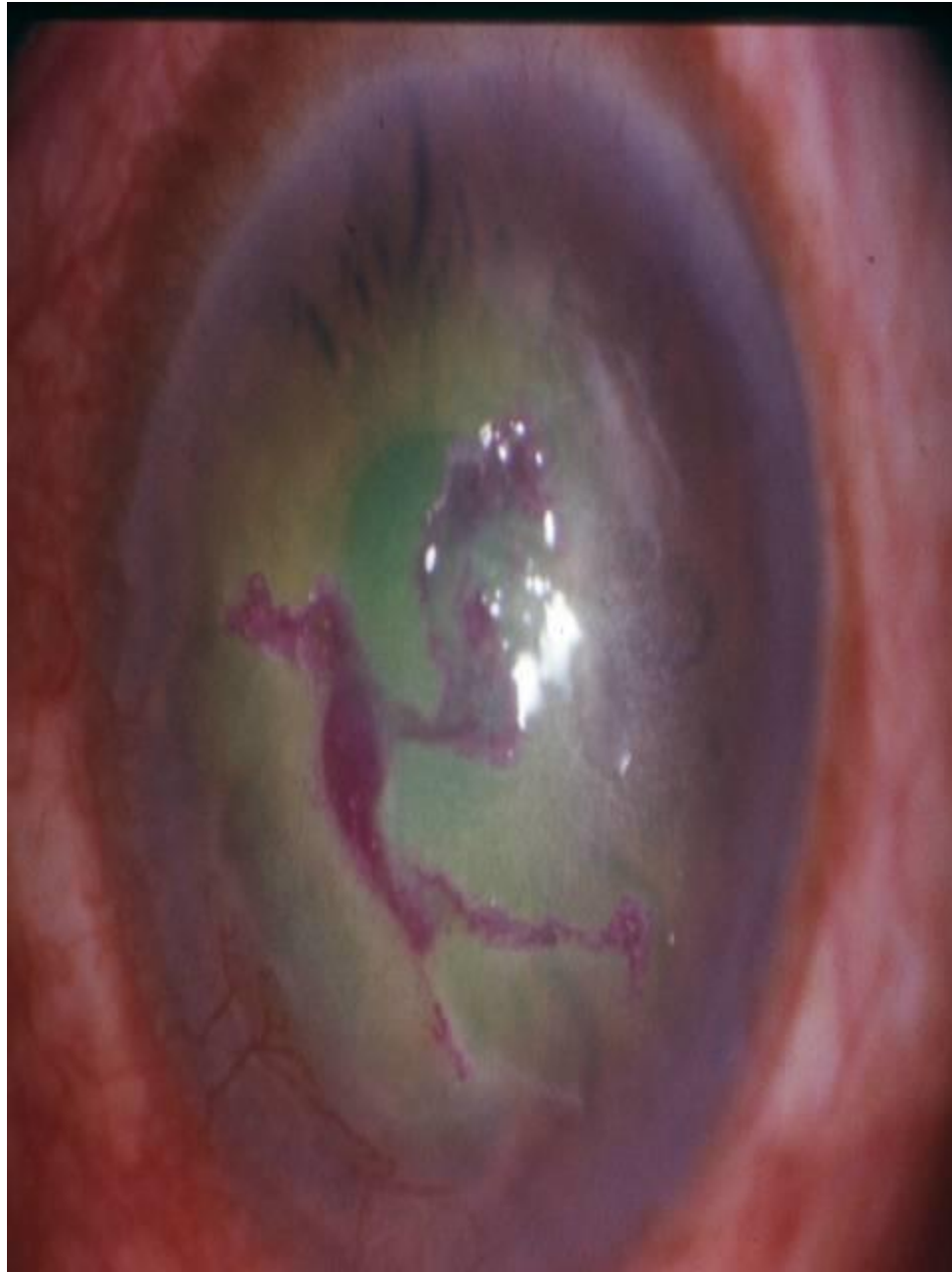
Uveitic Glaucoma Management

- Intractable uveitic glaucoma that is unresponsive to medical therapy may be treated with laser surgery.
 - LPI may prove to be difficult in inflammatory states, and
 - laser trabeculoplasty has proven to be ineffective
- Surgical iridectomy is the recommended procedure and is considered safer than filtration surgery.



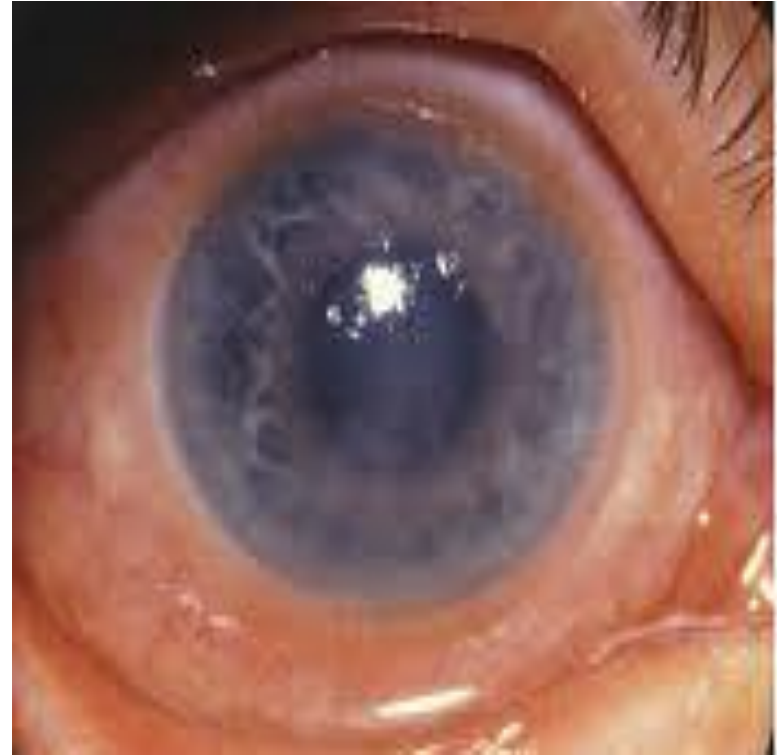Herpes Simplex Virus Keratitis

- HSV keratitis presents with:
 - varying irritation, pain, photophobia, and
 - generalized injection.
 - branching ulcers which stain with fluorescein and rose bengal
 - patients may report previous bouts of keratitis or cold sores
- Recurrent HSV is most common cause of central infectious keratitis
- Recurrence rate is 25% in first year, 50% during second year



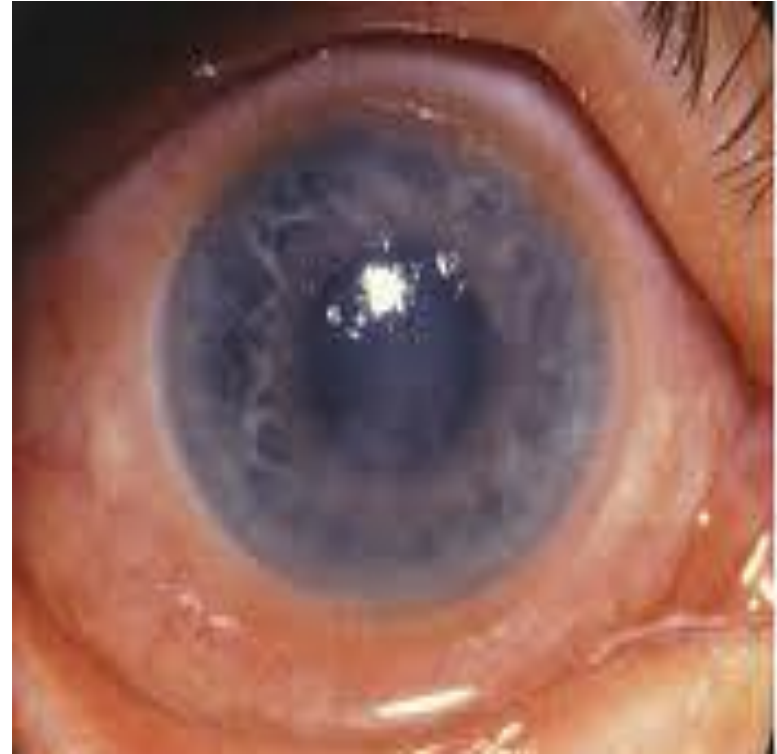HSV Keratouveitic Glaucoma

- Increased IOP is related to trabecular blockade or trabeculitis.
 - inflammatory cells, fibrin, and plasma proteins may produce a physical blockade of the trabecular meshwork
- Retrocorneal membrane obstruction of the angle may also contribute to rises in IOP



HSV Keratouveitic Glaucoma

- Thick and edematous trabecular bands, which may present clinically as limbitis, appears to obstruct trabecular outflow
- Posterior synechia formation could cause pupillary blockade and secondary angle-closure glaucoma.



HSV Keratouveitic Glaucoma

- glaucoma could be overlooked in a disease process that occurs in an acute, chronic, and intermittent fashion
- increased IOP as a consequence of prior damage to the trabecular meshwork by HSV keratouveitis can be overlooked.

HSV Keratouveitic Glaucoma

- The ocular signs of HSV keratouveitis that have presented with increased IOP include:
 - disciform keratouveitis (44%),
 - stromal keratouveitis (36%),
 - disciform keratitis (10%),
 - stromal keratitis (4%),
 - scleral keratitis/limbitis (2%), and
 - metaherpetic ulcer (4%).

HSV Keratouveitic Glaucoma

- The most striking feature noted by the authors was the preponderance of patients with uveitis in the group who developed increased IOP compared with the group who did not.
- Patients who developed herpetic ocular hypertension suffered an average of 2 attacks during the 4 years of observation.

HSV Keratouveitic Glaucoma

- The management of increased IOP and glaucoma occurring secondary to HSV keratouveitis is directed initially at halting or preventing activation of viral disease.
- After antiviral coverage has been provided, corticosteroids can have a profound and rapid effect on the inflammatory aspects of the disease, in particular the intraocular inflammation with a marked drop in IOP within a few days.

HSV Keratouveitic Glaucoma

- With long-term steroid use, the possibility of steroid-induced ocular hypertension should be kept in mind.
 - However, a drop in IOP from steroid suppression of the trabeculitis will precede any steroid-induced pressure rise.

HSV Keratouveitic Glaucoma

- Supplemental antiglaucoma medications may need to be added to adequately control the ocular hypertension.
- Suggested options include b-blockers, α -agonist, and carbonic anhydrase inhibitors (oral and topical).
- The IOP usually returns to normal as the intraocular inflammation resolves.
- Approximately 12% of patients with HSV keratouveitic glaucoma will develop persistent IOP elevation requiring chronic therapy.
 - Filtration surgery may be required occasionally.

Clinical Pearls

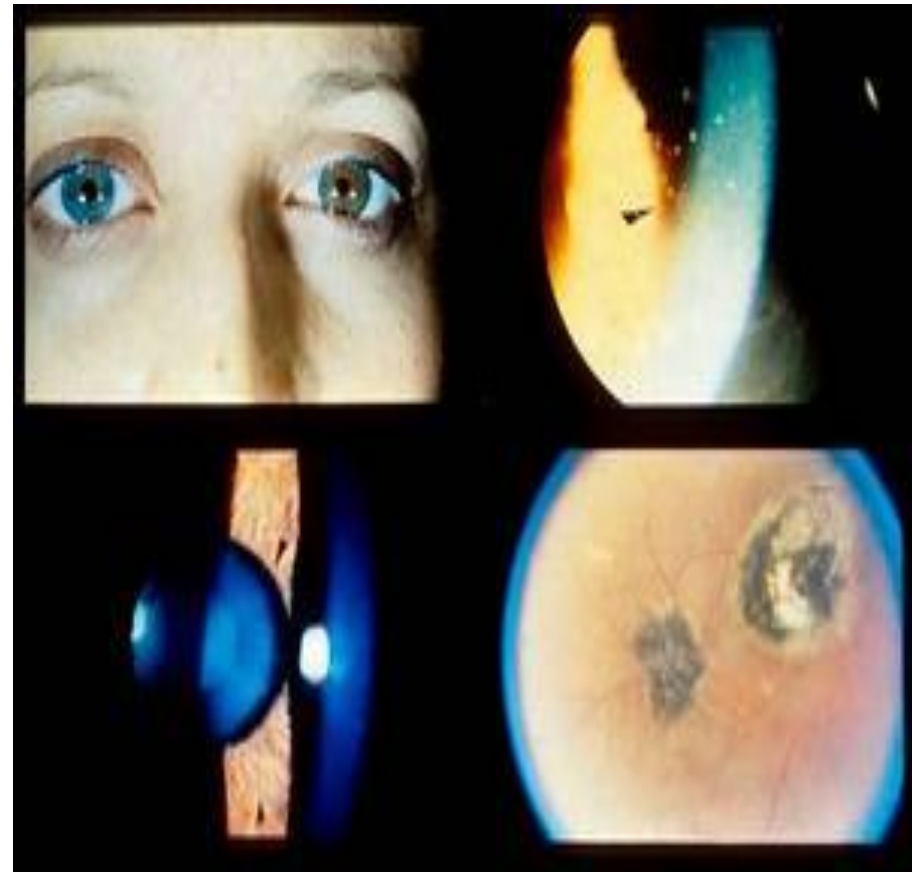
- Patients who develop a uveitis with an HSV keratitis are more likely to develop an ocular hypertensive state.
- Patients who develop increased IOP are more likely to have had frequent flare ups over a shorter period of time.
- Treatment of the viral infection is foremost with trying to reduce the overall inflammatory state.

Fuch's Heterochromic Iridocyclitis

- mild form of anterior uveitis associated with cataract and glaucoma
- most cases are unilateral,
- affect men and women equally, and begin in the fourth decade.
- increased IOP is seen in 13% to 59% of affected patients.

Fuch's Heterochromic Iridocyclitis

- this condition is characterized by:
 - iris atrophy with or without heterochromia,
 - posterior subcapsular lens opacities
 - gray-white nodules on the anterior surface of the iris, and
 - opacities in the vitreous



Fuch's Heterochromic Iridocyclitis

- postulated that the chronic inflammation causes permanent scarring of the outflow channels
- this form of uveitis does not respond well to treatment
- the IOP often responds poorly to medical therapy, including corticosteroids

Glaucomatocyclitic Crisis

- also referred to as *Possner-Schlossman syndrome*,
- produces significant elevation in IOP in association with recurrent episodes of mild anterior uveitis
- The clinical features include:
 - ciliary flush,
 - IOPs up to 60 mm Hg,
 - faint flare, and
 - keratitic precipitates.

Glaucomatocyclitic Crisis

- It is thought that the elevated IOP is caused by a trabeculitis
 - possibly involving prostaglandins
- The disorder is recurrent in nature and the patient should be monitored for visual field defects and optic nerve cupping.
- Treatment typically includes the use of corticosteroids, beta blockers and CAI's.

Steroid Induced Glaucoma

- Corticosteroid-induced glaucoma must be considered in the long-term management of ocular inflammation.
- Intraocular pressure elevation has been detected as early as 1 week and as late as several months after initiating treatment.
- The amplitude of IOP increase is dose-related and is allied closely to:
 - the potency,
 - frequency, and
 - route of administration and
 - the susceptibility of steroid response on the part of the patient.

Steroid Induced Glaucoma

- It has been established that topical or systemic corticosteroid administration is associated with significant elevations in IOP in 18% to 36% of the general population.
- The response rate is increased to between 46% and 92% in patients with primary open angle glaucoma and to 87% in first-degree relatives of patients with open angle glaucoma.

Steroid Induced Glaucoma

- The proposed mechanism of steroid-induced elevated IOP relates to impaired outflow facility through the TM.
 - Corticosteroids may decrease availability of catabolic enzymes and thus decrease breakdown of mucopolysaccharides that accumulate in the anterior chamber angle, retain water, and obstruct the trabeculae.

Steroid Induced Glaucoma

- Corticosteroids may also have a direct impact on trabecular cells through their interaction with cytoplasmic receptors and DNA binding sites.
 - Corticosteroids inhibit phagocytosis by TM cells that may lead to accumulation of cellular debris and increased resistance to aqueous outflow.
- Corticosteroids also reduce outflow facility by increasing tight junctions between TM endothelial cells.

Steroid Induced Glaucoma

- corticosteroids administered topically, by intraocular injection, or systemically are associated with a rise in intraocular pressure (IOP) and the development of glaucoma
- The rise in IOP has been shown to be related to the:
 - dose,
 - duration of administration,
 - type and route of administration of steroid.

Steroid Induced Glaucoma

- Intravitreal injections of triamcinolone acetonide (TA) have recently become a frequently used treatment for various intraocular proliferative or edematous diseases, including diabetic macular edema and central retinal vein occlusion.
- There have been several recent studies demonstrating a rise in IOP and the development of secondary glaucoma after intravitreal TA injections.

Steroid Induced Glaucoma

- In some patients, postinjection IOP elevation has been unresponsive to maximum medical therapy, necessitating surgical intervention including:
 - removal of the corticosteroid,
 - trabeculectomy,
 - Ahmed valve placement,
 - pars plana vitrectomy, or
 - a combination of trabeculectomy and vitrectomy with removal of corticosteroid.

Clinical Pearls

- Patients who have glaucoma or first degree relatives with glaucoma have a significantly increased prevalence of steroid induced IOP increases.
- IOP increase is directly related to:
 - Frequency of steroid use
 - Type of steroid
 - Route of administration
 - Duration of use

ANGLE CLOSURE GLAUCOMA SECONDARY TO MEDICATIONS

Acute Angle Closure Secondary to Medications

- At least one-third of Acute Angle Closure (AAC) cases are related to an over-the-counter or prescription drug.
- Drugs with alpha-1 adrenergic or anticholinergic effects can precipitate attacks of AAC mainly by mydriasis.
- Some drugs with no pupillary effect induce AAC by ciliochoroidal effusion:
 - E.g. sulpha-based drugs and anticoagulants

Acute Angle Closure Secondary to Medications

- Mechanisms by which a substance can induce angle-closure glaucoma:
 - pupillary dilatation,
 - forward displacement of the iris-lens structures, and
 - swelling of the ciliary body

Acute Angle Closure Secondary to Medications

- Both:
 - local (ocular drops, nasal and nebulized agents) and
 - systemic drugs (e.g. atropine, adrenaline, ephedrine, some psychoactive and antiepileptic drugs) can induce AAC
- Alpha-adrenergic agents cause mydriasis that can precipitate an attack in predisposed individuals that have shallow anterior chambers.

Acute Angle Closure Secondary to Medications

- Phenylephrine drops may induce AAC in about 0.03% of nonselected patients
- Cases have been reported after systemic administration of ephedrine for the flu

Angle Closure Secondary to Medications

- Angle-closure glaucoma has been mainly associated with:
 - TCAs,
 - low-potency antipsychotics,
 - topiramate and,
 - to a lesser extent, SSRIs.
- When patients with narrow angles are given TCAs, they all appear to experience induction of glaucomatous attacks.

Angle Closure Secondary to Medications

- Antipsychotics and SSRIs may lead to an added risk of developing angle-closure glaucoma, but only in predisposed eyes.
- Topiramate (anti-convulsant/epilipsy) can lead to an allergic-type reaction whereby structures of the lens and ciliary body are displaced, which results in angle-closure glaucoma.

Angle Closure Secondary to Medications

- Nebulized β_2 -adrenergic agents:
 - salbutamol, albuterol, terbutaline
 - used for bronchodilation in patients with asthma or chronic obstructive pulmonary disease.
 - can increase the intraocular pressure and induce transient angle closure.
 - stimulating ciliary body β_2 -adrenergic receptors promotes aqueous humour secretion.
 - angle closure is exacerbated by pupil dilation caused by the parasympathetic inhibitory effect

Anticholinergic agents

- Tropicamide is a short-acting anticholinergic commonly used to induce pupil dilation for fundus examination.
- Atropine, homatropine and cyclopentolate used to relax the ciliary muscle and dilate the pupil have long-acting anticholinergic action, and more frequently induce AAC

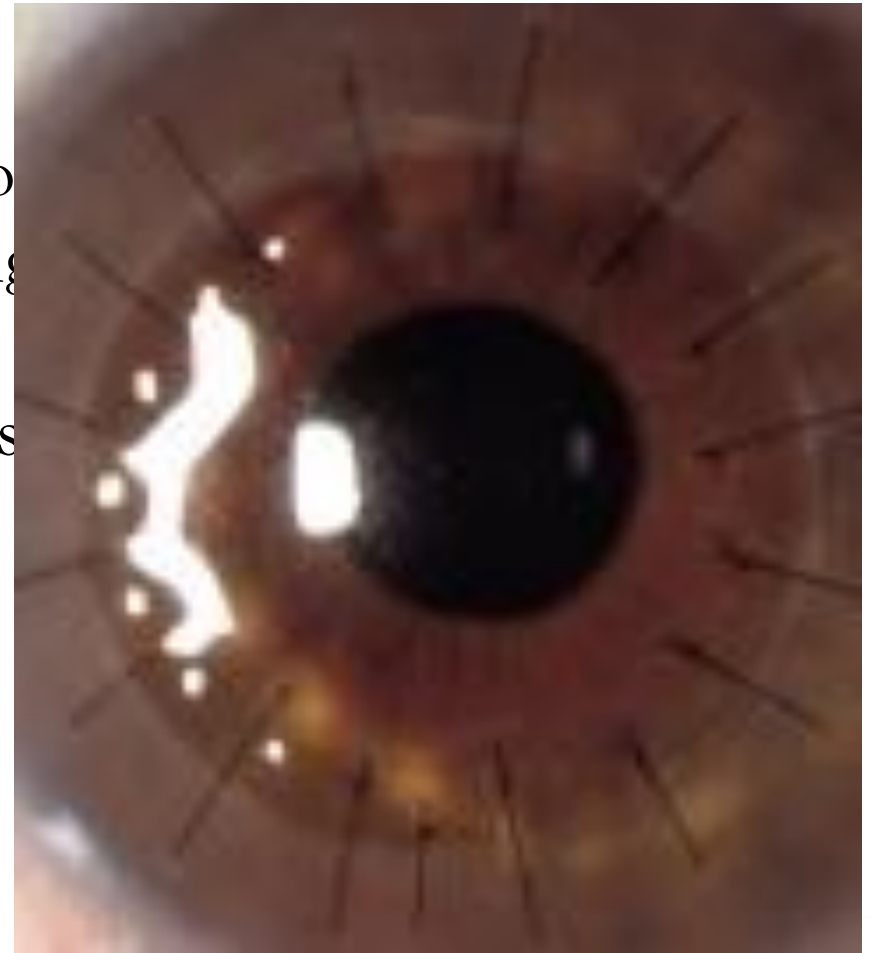Cholinergic agents

- Pilocarpine is used in some forms of glaucoma to constrict the pupil and increase aqueous outflow through the major outflow pathways.
- **However:**
 - it can induce AAC due to anterior movement of the iris-lens diaphragm, thus resulting in complete angle closure
 - eyes with zonular weakness or exfoliation syndrome seem to be particularly prone to developing miotic-induced angle closure

PKP AND GLAUCOMA

PKP and Glaucoma

- Irvine and Kaufman first reported a higher incidence of elevated IOP after PKP noting intraocular pressures higher than 25mmHg during the first post-operative week after corneal transplant surgery:
 - 37% of phakic eyes and
 - 88% in aphakic eyes



PKP and Glaucoma

- The incidence of glaucoma after PKP varies with the indication for PKP
 - increased IOP develops most frequently after PKP for aphakic bullous keratopathy and less frequently for eyes with Fuchs' corneal dystrophy and keratoconus
- risk factors for the development of glaucoma after PKP include:
 - pre-existing glaucoma,
 - presence of peripheral anterior synechiae,
 - corneal re-grafting,
 - history of ocular trauma, and
 - combined PKP and cataract extraction surgery

Mechanisms of Post-Keratoplasty Glaucoma

- Postsurgical glaucoma can be caused by:
 - pupillary block,
 - iritis,
 - hemorrhage,
 - steroid response,
 - malignant glaucoma, or
 - retained viscoelastic.

Mechanisms of Post-Keratoplasty Glaucoma

- Although increased IOP after PKP can develop in eyes with open or closed angles
 - **peripheral anterior synchia** is present in **87% of patients post-PKP.**
- Distortion of the angle, anterior and posterior to the trabecular meshwork, has also been implicated as a cause for increased IOP after PKP.

Mechanisms of Post-Keratoplasty Glaucoma

- Peripheral anterior synechiae secondary to corneal transplantation leads to progressive angle closure glaucoma that is often difficult to treat with medications or laser and frequently requires surgical intervention for adequate IOP control
- Corneal transplant donor size may also affect postkeratoplasty IOP.
 - using oversized donor tissue may decrease the incidence of increased IOP after PKP in the early post-operative course

Medical Management of PK-Glaucoma

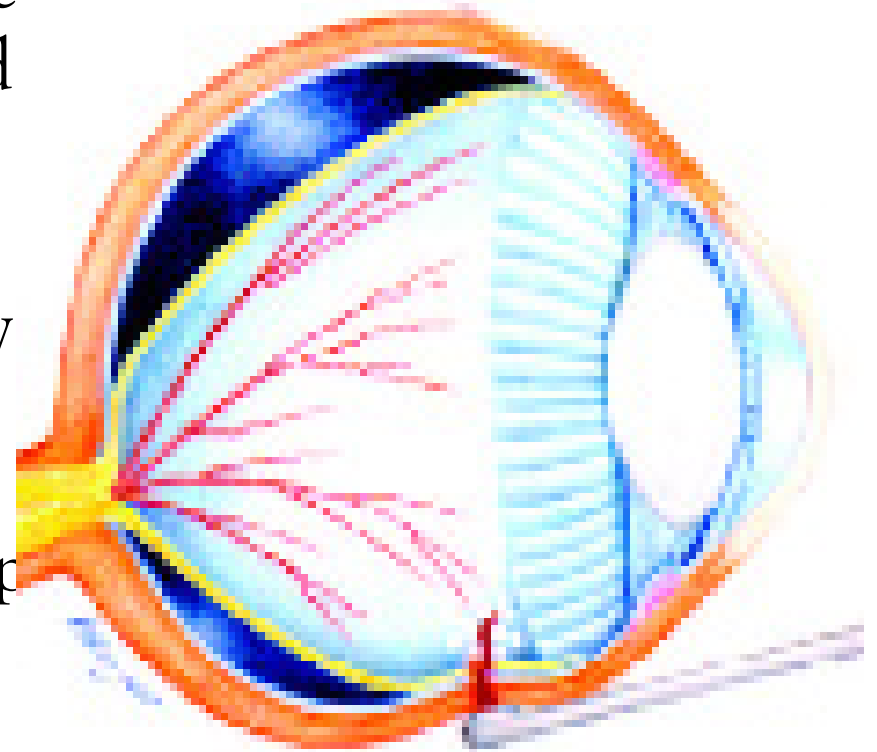
- The most commonly used and successful glaucoma medications are:
 - **topical beta-blockers and alpha-adrenergic agonists.**
- Prostaglandins are effective in lowering the IOP,
 - but case reports of increased incidence of inflammation associated with their use may compromise graft outcome and visual outcome if cystoid macular edema develops

Medical Management of PK-Glaucoma

- The use of miotics is usually ineffective and not recommended in the early post-operative period
 - pilocarpine causes break-down of the blood-aqueous barrier and shallows the anterior chamber with subsequent intraocular inflammation and potential development of peripheral anterior synechiae.
- Carbonic anhydrase inhibitors (CAIs) can be used topically or systemically.

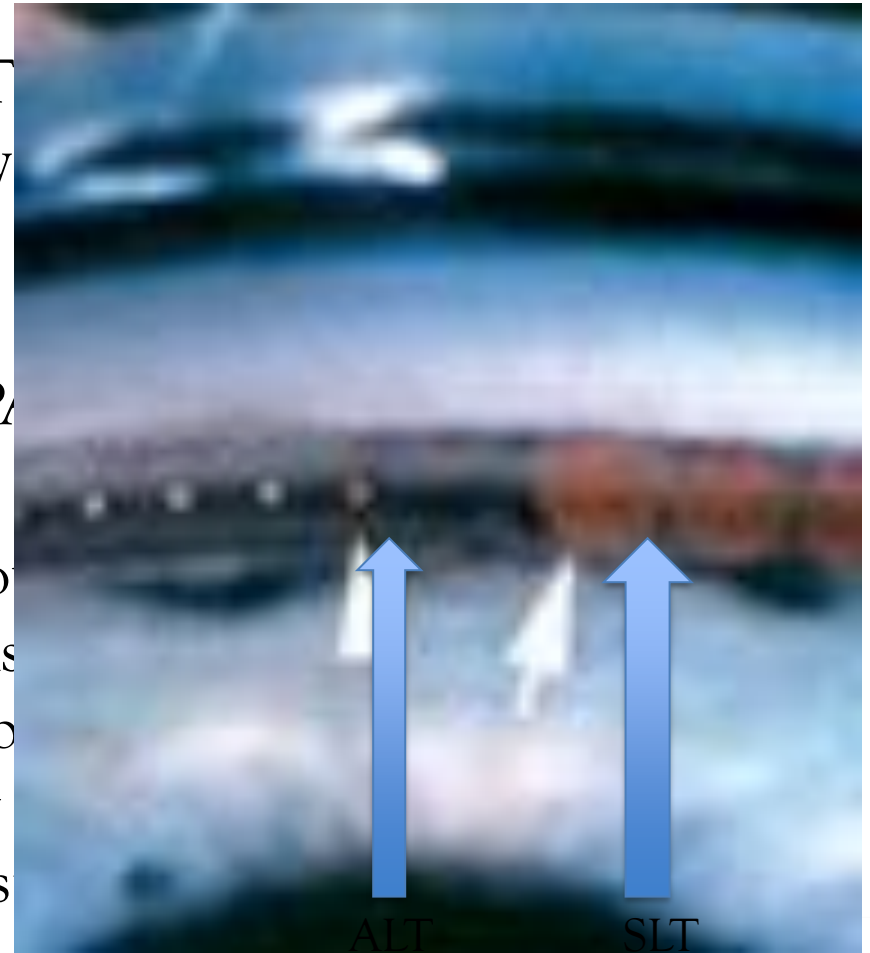
Cyclodestructive Procedures

- By ablating a portion of the ciliary body, IOP is lowered by decreasing aqueous humour production
 - destruction of the ciliary body can be achieved through transscleral application of cryotherapy or transscleral or endoscopic delivery of diode, krypton or Nd:YA laser.



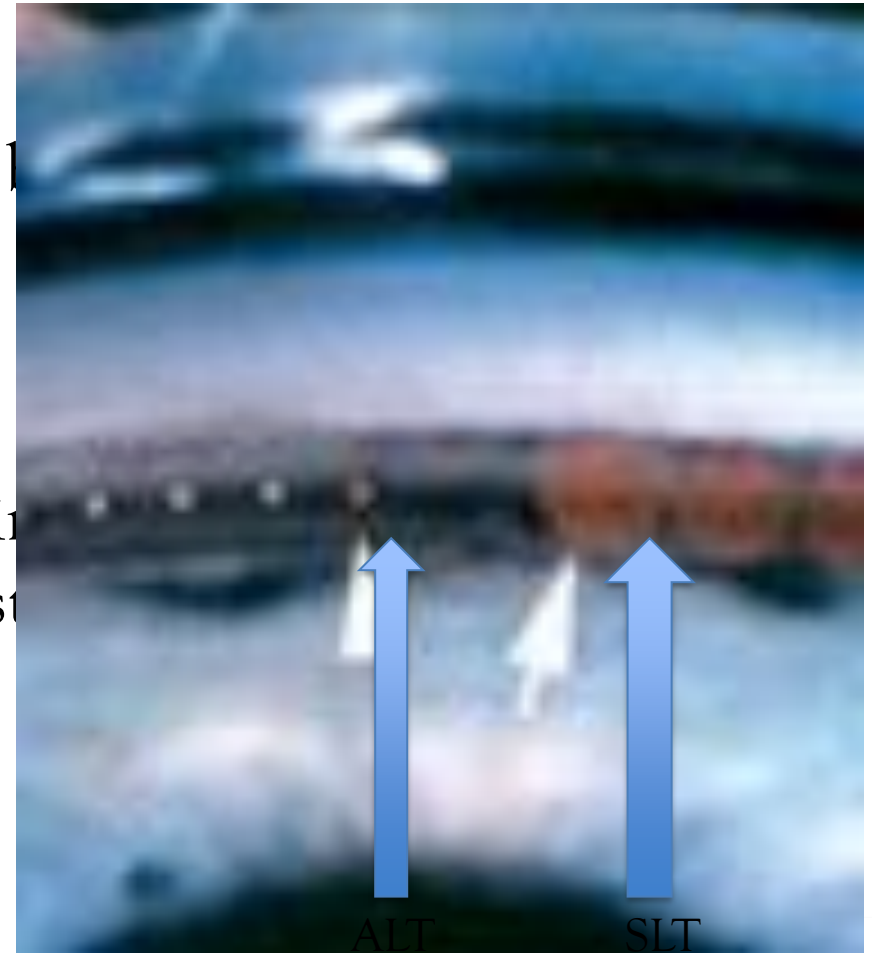
Laser Trabeculoplasty

- Argon laser trabeculoplasty (ALT) has been reported to successfully treat PK glaucoma
 - use of this modality is often limited by the formation of P₂ after keratoplasty.
 - Poor visibility of the TM through the corneal transplant may also limit its use as the laser may be applied ineffectively, possibly resulting in further angle closure



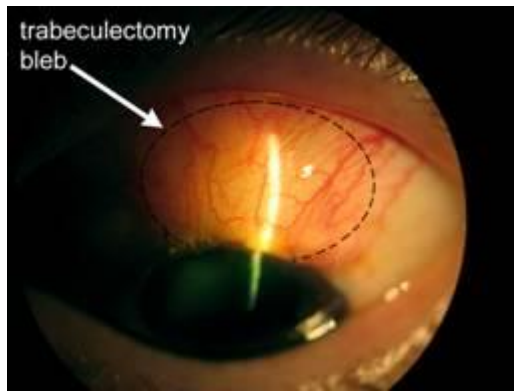
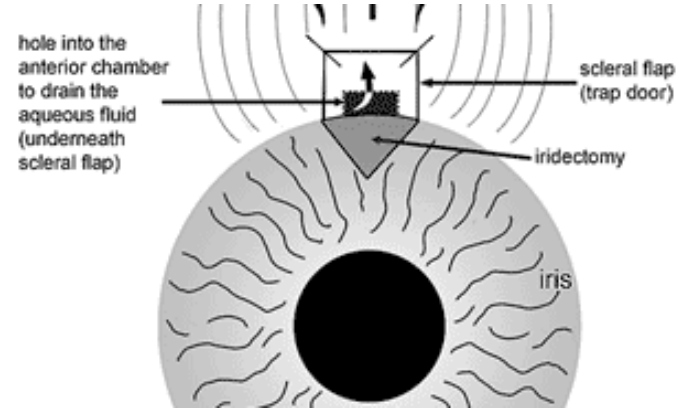
Laser Trabeculoplasty

- Use of selective laser trabeculoplasty is also limited by the poor visibility of the trabecular meshwork.
- Both procedures have limited clinical data to support their efficacy in treating glaucoma following keratoplasty.



Trabeculectomy

- Trabeculectomy with and without mitomycin-C has been shown to be successful in controlling intraocular pressure after keratoplasty
- The use of anti-metabolites improves IOP control and the success of trabeculectomy



Summary

- Glaucoma following penetrating keratoplasty (PKP) is one of the most common causes for irreversible visual loss and the second leading cause for graft failure after rejection.
- The management of penetrating keratoplasty and glaucoma (PKPG) remains controversial mainly because of the high risk of graft failure associated with the treatment.